



The role of the dental surgeon in the early diagnosis of oral cancer: a concise systematic review

Gabriele Altrão^{1,2*}, Alvaro da Rocha Mendes Filho^{1,2}, Leandro Moreira Tempest^{1,2}

¹ University Center North Paulista (Unorp) - Sao Jose do Rio Preto, Sao Paulo, Brazil.

² Post graduate and continuing education (Unipos), Sao Jose do Rio Preto, Sao Paulo, Brazil.

*Corresponding author: Gabriele Altrão, Unorp/Unipos - Post graduate and continuing education, Sao Jose do Rio Preto, Sao Paulo, Brazil.

Email: gabial71@hotmail.com

DOI: <https://doi.org/10.54448/mdnt21506>

Received: 05-23-2021; Revised: 09-28-2021; Accepted: 10-05-2021; Published: 10-16-2021; MedNEXT-id: e21506

Highlight

- ✓ Anamnesis and detailed clinical examination are essential for the prevention and treatment of oral cancer (OC).
- ✓ Basic knowledge in oral pathology is a requirement for all dental surgeons, as well as being always attentive to the detailed clinical examination.
- ✓ Perform biopsies whenever you notice tissue changes older than 15 days that have not healed.
- ✓ OC represents the 6th most common cancer in the world, with approximately 90% being represented by squamous cell carcinoma, and 10% represented by mesenchymal neoplasms (malignant neoplasm of cartilage tissue and salivary glands).
- ✓ The prevention of OC depends mainly on the elimination of risk factors involved in its etiopathogenesis.
- ✓ Every dental surgeon must emphasize and clarify the importance of self-examination to the patient.
- ✓ The main causes are tobacco, alcohol, poor oral hygiene, residual roots, local irritation, sun exposure.

Abstract

Introduction: Oral cancers (OC) represent more than 90% of cases. It is estimated that more than 400,000 new cases of oral cancer are diagnosed each year worldwide. OC is preventable as most of the different identified risk factors, such as tobacco use, alcohol consumption, and betel nut chewing, are behaviors that increase the likelihood of the disease. Surgical biopsy remains the gold standard, but adjunctive tools have been developed to aid diagnoses, such as vital toluidine blue staining and autofluorescence imaging.

Objective: To emphasize and present the importance of the dental surgeon in the early diagnosis and prevention of oral cancer. **Methods:** The survey was

conducted from July 2021 to August 2021 and developed based on Scopus, PubMed, Science Direct, Scielo, and Google Scholar, following the rules of Systematic Review-PRISMA. Study quality was based on the GRADE instrument and the risk of bias was analyzed according to the Cochrane instrument. **Results:** Early detection and treatment of OC were found to be important predictors for improving survival and reducing mortality. A thorough clinical inspection of the oral cavity can detect up to 99% of oral cancers. Other diagnostic types have been developed to help overcome the limits of standard oral clinical examination, highlighting toluidine blue staining, light-based detection techniques, and salivary biomarkers. Self-examination is an effective strategy to reduce the levels of mortality and morbidity caused by this pathology. A gain of 8.09% more in sensitivity and 11.36% more in specificity was observed with the fluorescence test. **Conclusion:** The findings clearly showed that early diagnosis of oral cancer is essential to increase the chances of cure and survival of patients, avoiding invasive surgical intervention. Currently, there are several diagnostic tools for screening and visual devices for the early detection of oral lesions through auxiliary methods, logically maintaining biopsy as the gold standard.

Keywords: Oral cancer; Prevention; Early diagnosis; Auxiliary techniques.

Introduction

Oral cancers (OC) represent more than 90% of cases [1]. Other examples of oral tumors include those of the minor salivary glands, melanomas, and

lymphomas [2]. It is estimated that more than 400,000 new cases of oral cancer are diagnosed each year in the world, with 2/3 of the cases occurring in Asian countries [1,3]. In Westerners, on the other hand, OC is infrequent. In this context, despite the epidemiological data, OC is preventable, since most of the different risk factors identified, such as tobacco use, alcohol consumption, and chewing betel nut, are behaviors that increase the probability of the disease. Thus, anticipating the diagnosis begins with the identification of potentially malignant lesions of the oral mucosa and inflammatory processes [4].

In this sense, clinical recognition and evaluation of lesions of the oral mucosa can detect up to 99% of cancers. According to WHO, the lesion needs to disappear within two weeks and must be biopsied. Surgical biopsy remains the gold standard for diagnosing oral cancer. Additionally, adjunctive tools have been developed to aid diagnoses, such as vital toluidine blue staining and autofluorescence imaging [4].

Oral cancer can be easily detected through relatively simple tests, and the prognosis of the disease is linked to the stage at which it is detected. Visualization of the OC is facilitated by the anatomical characteristics and by the location of the oral cavity, to dispense with the use of instruments of high technological complexity and hardly generate discomfort for the patient. Hence the importance of professional awareness for early diagnosis and the correct direction for treatment [5,6].

In this context, the etiology of OC is multifactorial, resulting from several factors that predispose to the development of this pathology, with a high incidence and mortality, and is among the 10 most common pathologies in the world [5]. The areas that suffer most from the disease are the tongue, specifically the posterior lateral border, mouth floor, gums, mucosa, tonsils, retromolar region, dorsum of the tongue, soft palate, and hard palate [5]. The survival rate of early diagnosis in the early stages ranges from 53% to 68%, while the diagnosis of advanced cancer is approximately 41% and 27% and in the late stage, it is regrettably 70 to 80% [6].

In this scenario, the most common type (94% to 96% of cases) of oral cancer is squamous cell carcinoma (SCC) or squamous cell carcinoma that affects the most common sites of this pathology are the tongue (26%) and the lower lip (23 %) [6,7]. Furthermore, OC was divided into categories such as salivary gland tumors, epithelial tumors, mesenchymal tumors, bone tumors, hematological tumors, odontogenic tumors, and others [7]. In this aspect, the dentist is the health professional who has an important role in the actions and a strategic role [8].

Therefore, this work aimed to highlight and present the importance of the dental surgeon in the early diagnosis and prevention of oral cancer.

Methods

Study Design

The rules of the Systematic Review Platform-PRISMA (Transparent report of systematic reviews and meta-analysis-HTTP: [//www.prisma-statement.org/](http://www.prisma-statement.org/)) were followed [9].

Research Strategy

The search strategies for this systematic review were based on the keywords (MeSH Terms): "Oral cancer; Prevention; Early diagnosis; Auxiliary techniques". The survey was conducted from July 2021 to August 2021 and was developed based on Scopus, PubMed, Science Direct, Scielo, and Google Scholar. In addition, a combination of the keywords with the Booleans "OR", "AND", and the operator "NOT" were used.

Study Quality and Risk of Bias

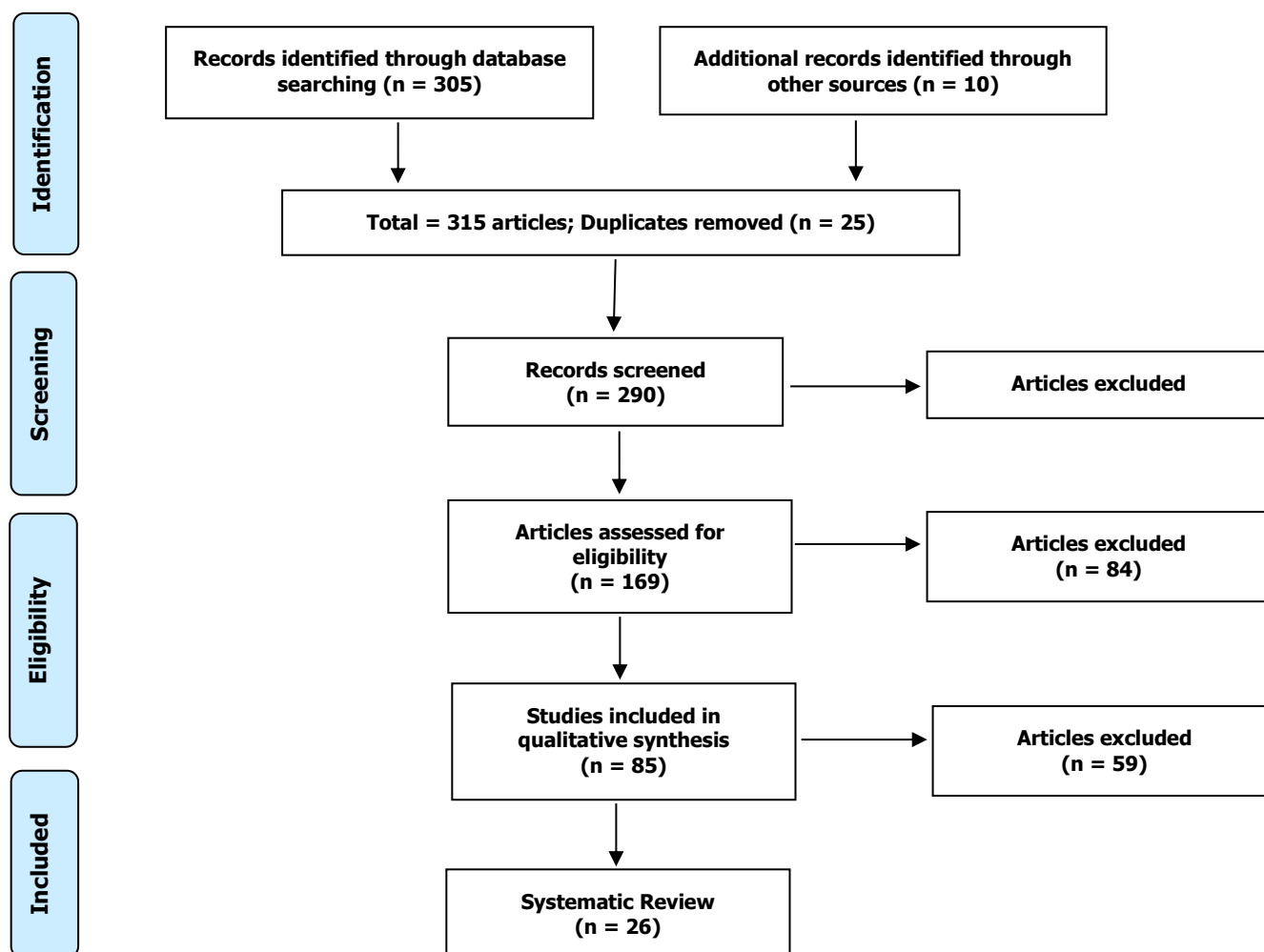
The quality of the studies was based on the GRADE instrument [10] and the risk of bias was analyzed according to the Cochrane instrument [11]. Two independent reviewers performed the research and study selection. Data extraction was performed by reviewer 1 and fully reviewed by reviewer 2. A third investigator decided on some conflicting points and made the final decision to choose the articles.

Results and Discussion

A total of 315 articles were found on oral cancer and early diagnosis. Initially, duplication of articles was excluded. After this process, the abstracts were evaluated and a new exclusion was performed, removing the articles that did not address the theme of this article. In total, 85 articles were fully evaluated and 26 were included and evaluated in this study (Figure 1).

Considering the Cochrane tool for risk of bias, the overall assessment in 3 studies with a high risk of bias and 2 studies with uncertain risk. The domains that presented the highest risk of bias were related to the number of participants in each study, and the uncertain risk was related to the safety and efficacy of early diagnosis and auxiliary techniques. Also, there was no funding source in the 2 studies and 1 study did not disclose information about the declaration of conflict of interest.

Figura 1. Eligibility.



After a restricted analysis of the studies, it was identified that the early detection and treatment of OC are important predictors to improve survival and reduce mortality [12]. The diagnostic process begins with a clinical oral examination, with visual inspection and digital palpation [13,15]. A thorough clinical inspection of the oral cavity can detect up to 99% of oral cancers [12].

In this context, in the initial period, the OC can be asymptomatic. It is necessary to identify persistent mouth sores and/or pain, localized changes in the appearance of the oral mucosa, localized changes in the consistency of the oral mucosa, persistent white or red spots or mixed white and red spots of the oral mucosa, raised spot or plaque on the oral mucosa, lump or persistent growth in the oral mucosa, a bleeding area located in the oral mucosa as proposed by the World Health Organization and the National Institute of Dental and Craniofacial Research and the American Dental Association [15].

In this sense, the routine cytological examination of a smear collected from the epithelial surface of the oral mucosa has low sensitivity and specificity to serve

as a predictive diagnostic tool for squamous cell carcinoma. Also, brush biopsy and micro biopsy have been proposed [16]. Besides, other types of diagnosis have been developed to help overcome the limits of the standard oral clinical examination [12], highlighting toluidine blue staining, light-based detection techniques, and salivary biomarkers [17].

Main Auxiliary Techniques and Diagnostic Practices

Toluidine Blue

Toluidine blue (TB) staining is a simple, inexpensive, and non-invasive technique to guide the diagnosis of malignant and premalignant lesions [18]. TB is a cationic metachromatic dye that chemically binds to the dysplastic epithelium (turning blue) [17]. In this sense, an aqueous solution at 1% v/v is applied for 30 seconds in the area of the suspected lesion, after the application of acetic acid at 1% v/v to remove the salivary and bacterial film [17].

Autofluorescence Imaging

Autofluorescent imaging can provide additional

information about the nature of the lesion [19], being an adjunct to visual and tactile clinical examination [20].

Salivary Biomarkers

Human saliva presents organic and inorganic molecules, proteins, peptides, and electrolytes, representing more than 100 biomarkers [21-23], pointing to pathological predictors such as viruses, cytokines (IL-1b, IL-8, TNF- α), receptors protein (CD44) [23,24], and DNA and RNA markers [23-25].

Also, self-examination is an effective strategy in reducing the levels of mortality and morbidity caused by this pathology, making clear the importance of health education in improving people's living conditions [1]. The dentist discloses the information, in addition to providing guidance, encouraging self-examination so that it can be diagnosed early, facilitating preventive work, thus giving the chance of cure [1,2].

Added to this, a study found that OC caused by chewing betel nuts has a poor prognosis. Thus, this study evaluated a Health Belief Model intervention using a lay health counselor (LHAs) for OC screening and mouth self-examination (MSE) in Aboriginal communities. Intervention (IG; n = 171) and control (CG; n = 176) groups. Participants in the IG were 2.04 times more likely to perform a monthly MSE than those in the CG and showed significantly higher levels of self-efficacy for CO and MSE [26].

Besides, a study with 98 patients (n = 49/group) evaluated the usefulness of a portable autofluorescence device (OralID) to detect oral premalignant lesions. The positive potential malignant lesions (PMLs) observed in the group without the use of OralID were 89.47% when compared with biopsies, while in the group with OralID it was 95.24%. Thus, a gain of 8.09% more sensitivity and 11.36% more specificity was observed with the OralID fluorescence test [27].

In addition, a study compared the quality of two different cell harvesting techniques. Thus, cell smears were collected from 10 orally healthy individuals from the palatal mucosa at two different times, baseline and 4 weeks later. The slides from both techniques were stained by Giemsa (n=40) and May-Gruenwald Giemsa (n=40). Liquid-based cytology showed statistically significant improvement compared to conventional glass slides. The thin layers, which were performed by liquid-based cytology, showed significantly better results in parameters such as uniform distribution, cell overlap, cell deformation, mucus, microbial colonies, and debris. The conventional glass slide approach showed more cell overlap and foreign material contamination than thin layers, which were performed by Orcellex® Brush cell collectors [28].

Also, a study evaluated 376 cases of odontogenic tumors from an oral pathology service regarding age, sex, anatomical location, and histological diagnosis. Keratocystic odontogenic tumors (31.6%) were the most common, followed by ameloblastoma (28.5%) and odontoma (22.6%). The mean age was 32.2 years, and more than half of the patients (52.1%) were in their second and third decades of life. The male/female ratio was 1:1.37, with a mandible/mandible ratio of 1:2.08 [29].

Conclusion

The findings clearly showed that early diagnosis of oral cancer is essential to increase the chances of cure and survival of patients, avoiding invasive surgical intervention. Currently, there are several diagnostic tools for screening and visual devices for the early detection of oral lesions through auxiliary methods, logically maintaining biopsy as the gold standard.

References

1. Warnakulasuriya S. Global epidemiology of oral and oropharyngeal cancer. *Oral Oncol.* 2009;45:309–316. doi: 10.1016/j.oraloncology.2008.06.002.
2. Dhanuthai K., Rojanawatsirivej S., Thosaporn W., Kintarak S., Subarnbhesaj A., Darling M., Kryshalskyj E., Chiang C.-P., Shin H.-I., Choi S.-Y., et al. Oral cancer: A multicenter study. *Med. Oral Patol. Oral Cir. Bucal.* 2017;23:e23–e29. doi: 10.4317/medoral.21999.
3. Montero P.H., Patel S.G. Cancer of the Oral Cavity. *Surg. Oncol. Clin. N. Am.* 2015;24:491–508. doi: 10.1016/j.soc.2015.03.006.
4. Abati S, Bramati C, Bondi S, Lissoni A, Trimarchi M. Oral Cancer and Precancer: A Narrative Review on the Relevance of Early Diagnosis. *Int J Environ Res Public Health.* 2020 Dec 8;17(24):9160. doi: 10.3390/ijerph17249160. PMID: 33302498; PMCID: PMC7764090.
5. Romero-Reyes M, Salvemini D. Cancer and orofacial pain. *Med Oral Patol Oral Cir Bucal.* 2016 Nov 1;21(6):e665-e671.
6. Aregbesola B, Soyele O, Effiom O, Gbotolorun O, Taiwo O, Amole I. Odontogenic tumours in Nigeria: A multicentre study of 582 cases and review of the literature. *Med Oral Patol Oral Cir Bucal.* 2018 Nov 1;23(6):e761-e766. doi: 10.4317/medoral.22473.
7. Irie MS, Mendes EM, Borges JS, Osuna LG, Rabelo GD, Soares PB. Periodontal therapy for patients before and after radiotherapy: A

- review of the literature and topics of interest for clinicians. *Med Oral Patol Oral Cir Bucal*. 2018 Sep 1;23(5):e524-e530. doi: 10.4317/medoral.22474.
8. Miranda J, Monteiro L, Albuquerque R, Pacheco JJ, Khan Z, Lopez-Lopez J, Warnakulasuryia S. Coffee is protective against oral and pharyngeal cancer: A systematic review and meta-analysis. *Med Oral Patol Oral Cir Bucal*. 2017 Sep 1;22(5):e554-e561. doi: 10.4317/medoral.21829.
 9. The PRISMA 2020 statement: an updated guideline for reporting systematic reviews. *BMJ* 2021; 372 doi: <https://doi.org/10.1136/bmj.n71>.
 10. H Balshem H, Grade guidelines: 3 rating the quality of evidence. *Journal of Clinical Epidemiology*, Maryland Heights, 64 (4) (2011) 401-406.
 11. Higgins, S Green, *Cochrane Handbook for Systematic Reviews of Interventions*. Version 5.1.0 [updated March 2011]. The Cochrane Collaboration; 2011.
 12. Walsh T., Liu J.L., Brocklehurst P., Glennly A.M., Lingen M., Kerr A.R., Ogden G.R., Warnakulasuriya S., Scully C. Clinical assessment to screen for the detection of oral cavity cancer and potentially malignant disorders in apparently healthy adults. *Cochrane Database Syst. Rev.* 2013 doi: 10.1002/14651858.CD010173.pub2.
 13. Ford P., Farah C. Early detection and diagnosis of oral cancer: Strategies for improvement. *J. Cancer Policy*. 2013;1:e2-e7. doi: 10.1016/j.jcpo.2013.04.002.
 14. Practice C. Guideline for the early detection of oral cancer in British Columbia 2008. *J. Can. Dent. Assoc.* 2008;74:245.
 15. Rethman M.P., Carpenter W., Cohen E.E., Epstein J., Evans C.A., Flaitz C.M., Graham F.J., Hujuel P.P., Kalmar J.R., Koch W.M., et al. Evidence-Based Clinical Recommendations Regarding Screening for Oral Squamous Cell Carcinomas. *J. Am. Dent. Assoc.* 2010;141:509-520. doi: 10.14219/jada.archive.2010.0223.
 16. Pentenero M., Val M., Rosso S., Gandolfo S. Microbiopsy a first-level diagnostic test to rule out oral dysplasia or carcinoma in general dental practice. *Oral Dis*. 2018;24:109-111. doi: 10.1111/odi.12735.
 17. Omar E. Current concepts and future of noninvasive procedures for diagnosing oral squamous cell carcinoma—A systematic review. *Head Face Med*. 2015;11:6. doi: 10.1186/s13005-015-0063-z.
 18. Li Y.-N., Lu R., Zhang J., Zhou G. Inter-and intra-observer agreement on the judgment of toluidine blue staining for screening of oral potentially malignant disorders and oral cancer. *Clin. Oral Investig*. 2018;23:1709-1714. doi: 10.1007/s00784-018-2595-7.
 19. De Veld D.C., Skurichina M., Witjes M.J., Duin R.P., Sterenberg H.J.C.M., Roodenburg J.L. Autofluorescence and diffuse reflectance spectroscopy for oral oncology. *Lasers Surg. Med.* 2005;36:356-364. doi: 10.1002/lsm.20122.
 20. Tiwari L., Kujan O., Farah C.S. Optical fluorescence imaging in oral cancer and potentially malignant disorders: A systematic review. *Oral Dis*. 2019;26:491-510. doi: 10.1111/odi.13071.
 21. Tecco S., Parisi M.R., Gastaldi G., Polizzi E., D'Amicantonio T., Zilocchi I., Gardini I., Gherlone E.F., Lazzarin A., Capparè P. Point-of-care testing for hepatitis C virus infection at an Italian dental clinic: Portrait of the pilot study population. *New Microbiol*. 2019;42:133-138. doi: 10.1111/cid.12370.
 22. Crespi R., Capparè P., Romanos G.E., Mariani E., Benasciutti E., Gherlone E. Corticocancellous porcine bone in the healing of human extraction sockets: Combining histomorphometry with osteoblast gene expression profiles in vivo. *Int. J. Oral Maxillofac. Implant.* 2011;26:866-872.
 23. Kaur J., Jacobs R., Huang Y., Salvo N., Politis C. Salivary biomarkers for oral cancer and pre-cancer screening: A review. *Clin Oral Investig*. 2018;22:633-640. doi: 10.1007/s00784-018-2337-x.
 24. Moretti M., Lissoni A., Gastaldi G., Arrigoni G., Doglioni C., Abati S. Expression of hexokinase ii in oral keratotic lesions with or without inflammation. *Front. Physiol*. 2019;10 doi: 10.3389/conf.fphys.2019.27.00057.
 25. Franzmann E.J., Donovan M.J. Effective early detection of oral cancer using a simple and inexpensive point of care device in oral rinses. *Expert Rev. Mol. Diagn.* 2018;18:837-844. doi: 10.1080/14737159.2018.1523008.
 26. Lee H, Ho PS, Wang WC, Hu CY, Lee CH, Huang HL. Effectiveness of a health belief model intervention using a lay health advisor strategy on mouth self-examination and cancer

screening in remote aboriginal communities: A randomized controlled trial. *Patient Educ Couns.* 2019 Dec;102(12):2263-2269. doi: 10.1016/j.pec.2019.07.001. Epub 2019 Jul 2. PMID: 31300183.

27. Saini R, Cantore S, Saini SR, Mastrangelo F, Ballini A, Santacroce L. Efficacy of Fluorescence Technology vs Conventional Oral Examination for the Early Detection of Oral Pre-Malignant Lesions. A Clinical Comparative Study. *Endocr Metab Immune Disord Drug Targets.* 2019;19(6):852-858. doi: 10.2174/1871530319666190119103255. PMID: 30659553.
28. Olms C, Hix N, Neumann H, Yahiaoui-Doktor M, Remmerbach TW. Clinical comparison of liquid-based and conventional cytology of oral brush biopsies: a randomized controlled trial. *Head Face Med.* 2018 May 29;14(1):9. doi: 10.1186/s13005-018-0166-4. PMID: 29843756; PMCID: PMC5975412.
29. Lima-Verde-Osterne R, Turatti E, Cordeiro-Teixeira R, Barroso-Cavalcante R. The relative frequency of odontogenic tumors: A study of 376 cases in a Brazilian population. *Med Oral*

Patol Oral Cir Bucal. 2017 Mar 1;22(2):e193-e200.

Acknowledgement

Nil.

Funding

Not applicable.

Data sharing statement

No additional data are available.

Conflict of interest

The authors declare no conflict of interest.

About the License

© The authors (s) 2021. The text of this article is open access and licensed under a Creative Commons Attribution 4.0 International License.