



## Successful adaptation during COVID-19 pandemic: suspected head and neck cancer biopsies under local anaesthetic

Fergus Cooper<sup>1</sup>, Hassan Baig<sup>2</sup>, Panagiotis Asimakopoulos<sup>1</sup>, Kim W Ah-See<sup>1</sup>, Muhammad Shakeel<sup>1,\*</sup>

<sup>1</sup> Department of otolaryngology-head and neck surgery, Aberdeen Royal Infirmary, Aberdeen, AB25 2ZN, UK

<sup>2</sup> Foundation Year doctor, Department of surgery, Ninewells hospital, NHS Tayside, Dundee, UK

\*Corresponding author Email: [drshakeel@doctors.org.uk](mailto:drshakeel@doctors.org.uk)

DOI: <https://doi.org/10.34256/mdnt2013>

Published: 16-11-2020

**Abstract:** Patients with a suspicious lesion in the head and neck region, including the pharynx and larynx, often undergo biopsy under general anaesthetic. This is a long established practice but lately, biopsy of such lesions under local anaesthetic in the outpatient setting is promoted. During the current COVID-19 pandemic our access to the operating theatre is significantly reduced. We have, therefore, modified our practice to allow us to carry out such biopsies under local anaesthetic in the outpatient setting. We share our experience with 20 patients who successfully underwent this procedure. The patients reported no adverse effects. We would encourage colleagues in other units to consider this option when dealing with such patients during the pandemic.

**Keywords:** COVID-19; Pandemic; Head and neck cancer; biopsy; local anaesthetic; outpatient

### Key learning points:

1. In selected patients, biopsies of oropharyngeal lesions including the tonsils can be performed under local anaesthetic safely.
2. The technique described was found to be well tolerated by the patients and there were no adverse outcomes.
3. Performing biopsies under local anaesthetic eliminates the morbidity associated with general anaesthesia.
4. Performing biopsies under local anaesthetic increases operating room availability which is particularly important in the current economic climate and considering the covid-19 pandemic.
5. Based on our experience, it would appear that performing biopsies under local anaesthetic in the office setting reduces the time from initial consultation to reaching a decision regarding treatment.

### 1. Introduction

In response to an advice statement from the Scottish Health Technologies Group (SHTG) asking clinicians to consider utilisation of outpatient biopsy for the prompt and cost effective diagnosis of head and neck cancer [1], we would like to share our successful recent local experience.

Traditionally, examination under anaesthesia (EUA) using general anaesthetic in patients with suspected oropharyngeal cancers is carried out to examine the post-cricoid and upper oesophagus for a synchronous primary, but this area can also be assessed using trans-nasal oesophagoscopy or intraluminal contrast imaging. EUA is also carried out to determine resectability of tumours in centres where transoral laser or robotic microsurgies are performed and in certain patients it would remain the preferred option. The concept of outpatient biopsy with or without local anaesthetic is very well-established and widely used [2, 3]. Our rate of performing these biopsies has increased further since the covid-19 pandemic and the subsequent reduced availability of operating theatres.

### 2. Aim

To share our experience of carrying out biopsy of a suspicious lesion in the head and neck region under local anaesthetic in an outpatient setting.

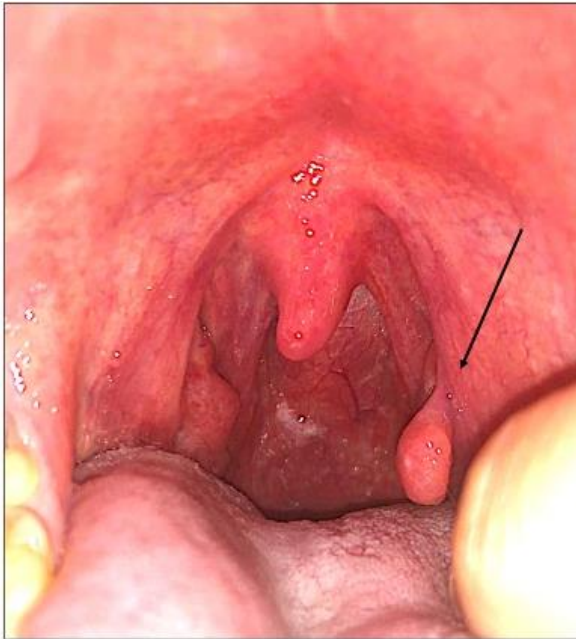### 3. Case Description

We have a short case series of patients who had a head and neck lesion amenable to biopsy under local anaesthetic. The patients were assessed in our

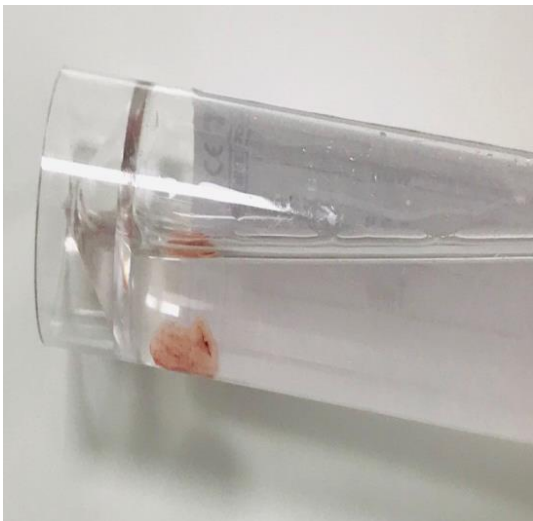


head and neck clinic with suspected lesions and were offered biopsy under local anaesthetic if the lesion could be seen easily (Figures 1-5). Some of these cases are described below:

A 26 year old Caucasian male was noticed to have a pedunculated lesion arising from the left tonsil (Figure 1). He was seen in clinic and under local anaesthetic the lesion was excised with scissors. He made an uneventful recovery and the final histology revealed it to be a benign papilloma (Figure 2)



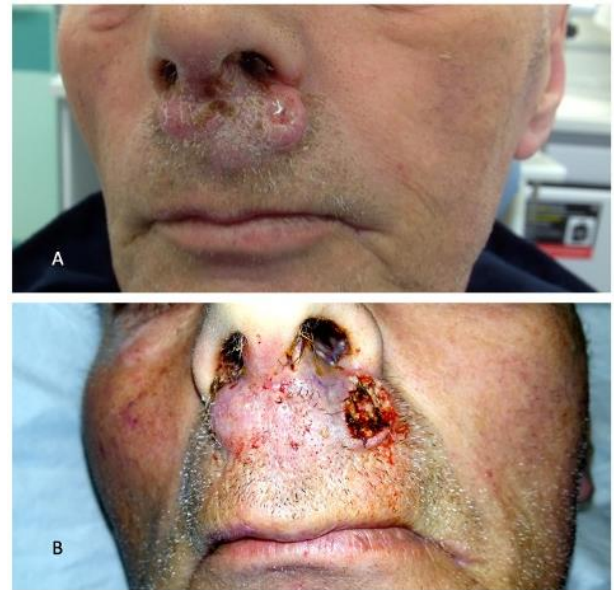**Figure 1** Oropharynx clearly showing a pedunculated polyp arising from the left tonsil (black arrow).



**Figure 2** The excised polyp shown in figure 1. The specimen in formalin ready to be sent to the pathology department. Histology confirmed it to be a squamous papilloma.

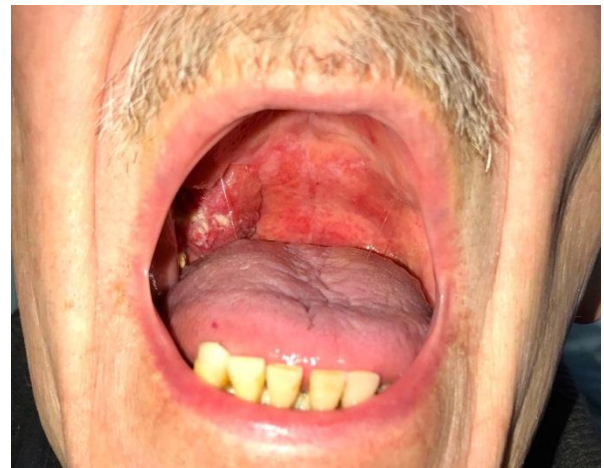A 60 years old Caucasian male was suspected to have an advanced nasal tumour (Figure 3). A punch

biopsy under local anaesthetic confirmed it to be squamous cell carcinoma.



**Figure 3** A large swelling involving the columella of nose, nasal floor and upper lip (A). The biopsy was taken under local anaesthetic using a 6 mm biopsy punch (B)

A 68 year old Caucasian male presented with an exophytic lesion in his oropharynx that was centred on the right soft palate and adjacent lateral pharyngeal wall (Figure 4).



**Figure 4** A large exophytic lesion could be seen in the right oropharynx proven to be SCC on biopsy under local anaesthetic.

The table below (Table 1) demonstrates 20 cases of patients with suspicious head and neck region lesions where we have performed local anaesthetic biopsy. We also present the turnaround times between initial consultation and performing the biopsy, and from the biopsy to the histological findings. All cases of malignancy were discussed in the Head and Neck multidisciplinary team (MDT) meeting within 7 days of the result.

**Table 1** Characteristics of study group

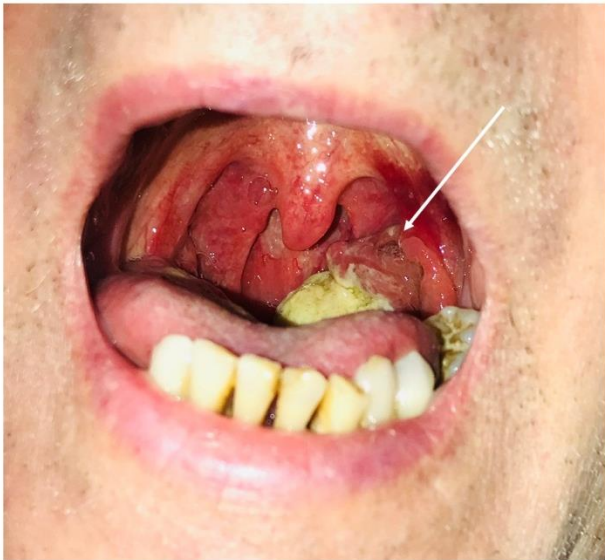Number	Age of patient	Site of lesion	Time from initial consultation to biopsy (days)	Diagnosis from biopsy	Time from biopsy to result (days)	TNM 8 staging
1	51	Tonsil (R)	0	P16 positive poorly differentiated basaloid SCC	9	T1 N1
2	58	Tonsil (L)	0	P16 positive poorly differentiated basaloid SCC	11	T1 N0
3	39	Tonsil (L)	25	P16 positive poorly differentiated basaloid SCC	19	T4a N1
4	77	Tonsil (L)	18	P16 negative SCC in situ. (FNA neck node = SCC)	3	T4a N3
5	73	Tonsil (L)	23	P16 positive poorly differentiated basaloid SCC	7	T4 N1
6	66	Tonsil (L)	19	P16 negative moderately differentiated keratinising SCC	3	T2 N3b
7	66	Tonsil (R)	0	P16 positive poorly differentiated basaloid SCC	11	T2 N1
8	55	Tonsil (L)	1	HPV positive moderately differentiated SCC	12	T4b N2b
9	57	Tonsil (L)	0	P16 negative poorly differentiated invasive SCC	8	T2 N3
10	85	Tonsil (L)	7	B-cell non Hodgkin Lymphoma	6	NA
11	63	Tonsil (L)	0	Benign tonsil tissue	7	N/A
12	27	Tonsil (L)	6	Squamous papilloma	15	NA
13	79	Tonsil (R)	2	P16 negative moderately differentiated keratinising SCC	9	T3 N1
14	68	Soft palate (R)	1	moderately differentiated SCC	12	T4 N2b
15	60	Floor of mouth (L)	0	Moderately differentiated keratinising SCC	7	T2 N0
16	61	Floor of mouth (L)	0	Moderately differentiated SCC	8	T4a N2c
17	69	Tongue base (L)	4	Moderately differentiated SCC	10	T4 N3
18	52	Postnasal space (L)	43	undifferentiated non-keratinising nasopharyngeal carcinoma	13	T4 N2
19	60	Nose (L)	10	moderately differentiated SCC	4	T4 N1
20	71	Nose (L)	0	moderately differentiated SCC	25	T4b N1 M1

HPV = Human papilloma virus; Squamous cell carcinoma = SCC; Right = R; Left = L.

#### 4. Discussion

The technique we employ for local anaesthetic biopsies of the oropharynx involves the patient sitting on a reclining chair with head support. The ENT surgeon should have a good head light and suction available. Lidocaine or Lidocaine with Phenylephrine throat spray is applied topically to the area to be biopsied. The area is then infiltrated with 2-4mls of Lidocaine 2% with 1:80,000 Adrenaline via a dental

needle and syringe, using a Lack tongue depressor if required. If the area being biopsied is a tonsil, the medial exophytic portion is targeted. A 6mm punch is used along with Blakesley forceps and disposable scissors to excise multiple pieces of the lesion for biopsy (Figure 5).



**Figure 5** Exophytic tumour involving the left oropharynx. A punched out area (white arrow) could be seen where a 6mm biopsy punch was used to take the biopsy under local anaesthetic in the clinic.

We have found that once anaesthetised, the tonsil can be held with the Blakesley forceps and retracted medially and superiorly without significant distress to the patient. In our experience, the bleeding is controllable with 6% hydrogen peroxide gargles (5mls diluted in 20mls water) and suction. We have not had to utilise bipolar forceps for haemostasis for these biopsies, however, this is available in our clinic area for use if needed.

## 5. Conclusion

We have found this method of biopsy to be safe in selected patients and beneficial to some by avoiding the risks of general anaesthesia. On verbal feedback, all of our patients were satisfied with the procedure performed and did not report any adverse effects. We believe that such a procedure can be used in well selected cases in order to mitigate cost and to obtain a faster histopathological diagnosis regardless of the pandemic and particularly in facilities where there is limitation in theatre availability. We advocate the use of this technique within Otolaryngology departments with a similar setup for selected patients.

## References

[1] SHTG Advice statement: Outpatient biopsy, for diagnosis of suspicious lesions of the larynx, pharynx and tongue base. Healthcare Improvement Scotland, October 2018. Advice statement 012-18.

[2] C.H. Zalvan, D.J. Brown, S.J. Oiseth, R.M. Roark, Comparison of trans-nasal laryngoscopic office based biopsy of laryngopharyngeal lesions with traditional operative biopsy, *European Archives of Oto-Rhino-Laryngology*, 270(9) (2013) 2509-2513. [DOI](#) | [PubMed](#)

[3] D.J. Wellenstein, J.K. de Witt, H.W. Schutte, J. Honings, F.J.A. van den Hoogen, H.A.M. Marres, R.P. Takes, G.B. van den Broek, Safety of flexible endoscopic biopsy of the pharynx and larynx under topical anesthesia, *European Archives of Oto-Rhino-Laryngology*, 274(9) (2017) 3471-3476. [DOI](#) | [PubMed](#)

## Acknowledgement

Nil

## Funding

Nil

## Authors Contribution

Data collection, analysis, drafting and finalising the final manuscript (FC, HB, PA, KWAS). Designing the study, data collection, analysis, drafting and finalising the final manuscript(MS).

## Data sharing statement

No additional data are available

## Ethics Approval

Approval was sought and granted by the Departmental Ethics Committee.

## Informed consent

Participant gave written informed consent to participate in this study.

## Conflict of interest

The authors declare no conflict of interest.

## About The License

© The author(s) 2020. The text of this article is open access and licensed under a Creative Commons Attribution 4.0 International License