



# Major approaches of the use of FRP and Bio-Oss® in bone regeneration and elevation for implantology: a concise systematic review

Edmilson da Silva Esteves<sup>1,2\*</sup>, Elias Naim Kassis<sup>1,2</sup>, Sandey Bernardes da Silva Carvalho<sup>1,2</sup>

<sup>1</sup> University Center North Paulista (Unorp) - Sao Jose do Rio Preto, Sao Paulo, Brazil.

<sup>2</sup> Post graduate and continuing education (Unipos), Sao Jose do Rio Preto, Sao Paulo, Brazil.

\*Corresponding author Email: Edmilson da Silva Esteves,  
Unorp/Unipos - Post graduate and continuing education,  
Sao Jose do Rio Preto, Sao Paulo, Brazil.

E-mail: diestevez09@gmail.com

DOI: <https://doi.org/10.54448/mdnt21501>

Received: 05-17-2021; Revised: 09-15-2021; Accepted: 09-15-2021; Published: 09-21-2021; MedNEXT-id: e21501

## Abstract

**Introduction:** In the scenario of maxillary sinus surgery for the later practice of implantology, several surgical techniques can be used to reconstruct the atrophic alveolar ridge, isolated techniques or associated with autogenous, allogeneic, xenogenous, and alloplastic biomaterials. The autogenous bone graft is the only one capable of presenting three important biological properties (osteogenesis, osteoinduction, and osteoconduction) guaranteeing a self-regenerative potential. Platelet concentrates have been proposed as regenerative materials in tissue regeneration procedures. Among the platelet concentrates proposed in the literature, there is FRP that act as autogenous platelet aggregates with osteoinductive properties. As an example of xenografts, Bio-Oss® stands out, being a bovine bone biomaterial. The excellent osteoconductive properties of Bio-Oss® lead to predictable and efficient bone regeneration, becoming an integral part of bone structure and volume.

**Objective:** To carry out a brief systematic review of the main considerations for the use of fibrin-rich plasma and Bio Oss® in bone regeneration for implant dentistry.

**Methods:** The survey was conducted from May 2021 to July 2021 and developed based on Scopus, PubMed, Science Direct, Scielo, and Google Scholar, following the rules of Systematic Review-PRISMA. Study quality was based on the GRADE instrument and the risk of bias was analyzed according to the Cochrane instrument.

**Results:** The lack of bone in the alveolar crests has been a major problem in functional aesthetic recovery in patients who have suffered dentoalveolar trauma, traumatic tooth extractions, congenital tooth loss,

maxillary and mandibular pathologies, in addition to infections due to the emotional and possibility of deformity. In this context, implant dentistry stands out as a modern method of oral rehabilitation for totally or partially edentulous patients. For this method to develop properly, bone integration of the implant into the recipient bone tissue must occur. It was documented that the combination of biomaterial and FRP significantly improved bone regeneration in the peri-implant area. Placing the implant with the simultaneous use of the FRP creates a good relationship between hard tissue and soft tissue. FRP is used as an adjuvant to Bio-Oss® particles for bone augmentation in the maxillary sinus. **Conclusion:** Based on literary findings, it was shown that FRP is favorable for bone formation processes for dental implants, especially when combined with Bio-Oss®.

**Keywords:** Implantology. Bone regeneration. Maxillary sinus surgery. Fibrin-rich plasma. Bio-Oss®. Biomaterials.

## Introduction

In the scenario of maxillary sinus surgery for the later practice of implant dentistry, the maxillary sinus is the largest of the paranasal sinuses and its function is to contribute to phonation resonance, conditioning the air we breathe and aiding in the production of mucus in the nasal cavity [1]. It also acts to equalize barometric pressures in the nasal cavity, which is covered by a membrane called Schneider's membrane. This membrane consists of a cylindrical pseudostratified epithelium with calciform cells that produce mucus. The importance of knowing the constitution of this epithelium is due to the

fact that these hair cells play a fundamental role in the physiology of the maxillary sinus. While the calciform cells produce mucus, these cilia generate movements that cause this mucus to be directed to the drainage site of the maxillary sinus [1,2].

When a dental element is lost in the posterior region of the maxilla, there is natural reabsorption of the alveolar process and, at the same time, pneumatization of the maxillary sinus will occur. It will increase its volume towards the place where the roots existed and this will often make it difficult or impossible to restore implants at the site [3]. For this reason, the maxillary sinus floor elevation procedure should be performed, or short implants when possible. When grafting procedures are needed, our focus is often on the type of biomaterial to be used and, in fact, the success and predictability of our results do not depend only on the biomaterial [3].

It is also necessary to consider the type of defect to be treated, its morphology. The morphology will impact mainly because the defects have different vascularization capacities, different osteogenic cell recruitment capacities, different graft natural stabilization capacities, therefore, we must consider the characteristics of the biomaterials that we must employ, but also the characteristics of the bed and the bone defect that we intend to treat [4].

In addition, several surgical techniques can be used to reconstruct the atrophic alveolar ridge, isolated techniques, or associated with autogenous, allogeneic, xenogeneic, and alloplastic biomaterials. The autogenous bone graft is the only one capable of presenting three important biological properties (osteogenesis, osteoinduction, and osteoconduction) guaranteeing a self-regenerative potential [3]. As a disadvantage to autogenous bone graft, the need for second surgical access in the donor area is highlighted, resulting in longer surgical time, morbidity, and a consequent greater resistance of the patient to the proposed treatment [3].

In this context, allogeneic, xenogenous, and alloplastic bone grafts are an alternative for the treatment of bone deficiencies in the jaws, as they avoid the need for a second surgical approach. But due to the need for processing to eliminate antigenic components, these grafts are uniquely osteoconductive with a lower bone formation potential compared to the autogenous bone graft [5]. In order to increase the bone formation potential of these grafts, combinations have been proposed to obtain better regenerative conditions through volume preservation and induction of cell migration differentiation [5-8].

Also in this context, in the last 20 years, platelet concentrates have been proposed as regenerative

materials in tissue regeneration procedures. Among the platelet concentrates proposed in the literature, there are PRP and FRP that act as autogenous platelet aggregates with osteoinductive properties. These biomaterials, due to their low morbidity and possible regenerative potential, have been indicated for use in combination with other biomaterials or even alone [4,7].

Still, as an example of xenografts, Bio-Oss® stands out, being a bovine bone biomaterial. The excellent osteoconductive properties of Bio-Oss® lead to predictable and efficient bone regeneration, becoming an integral part of bone structure and volume [6]. The highly porous structure of Bio-Oss® offers much space for the formation of the blood vessels (angiogenesis) and the deposit of neoformed bone [8]. The microstructure of the surface of Bio-Oss® supports the 'excellent growth' of osteoblasts, which are responsible for 'bone formation' [9].

Therefore, the present study aimed to carry out a brief systematic review of the main considerations for the use of fibrin-rich plasma and Bio-Oss® in bone regeneration for implant dentistry.

## Methods

### Study Design

The rules of the Systematic Review Platform-PRISMA (Transparent report of systematic reviews and meta-analysis-HTTP: [//www.prisma-statement.org/](http://www.prisma-statement.org/)) were followed [10].

### Research Strategy

The search strategies for this systematic review were based on the keywords (MeSH Terms): "*Implantology. Bone regeneration. Maxillary sinus surgery. Fibrin-rich plasma. Bio-Oss®. Biomaterials*". The survey was conducted from May 2021 to July 2021 and was developed based on Scopus, PubMed, Science Direct, Scielo, and Google Scholar. In addition, a combination of the keywords with the Booleans "OR", "AND", and the operator "NOT" were used to target the scientific articles of interest.

### Study Quality and Risk of Bias

The quality of the studies was based on the GRADE instrument [11] and the risk of bias was analyzed according to the Cochrane instrument [12]. Two independent reviewers performed the research and study selection. Data extraction was performed by reviewer 1 and fully reviewed by reviewer 2. A third investigator decided on some conflicting points and made the final decision to choose the articles.

## Results and Discussion

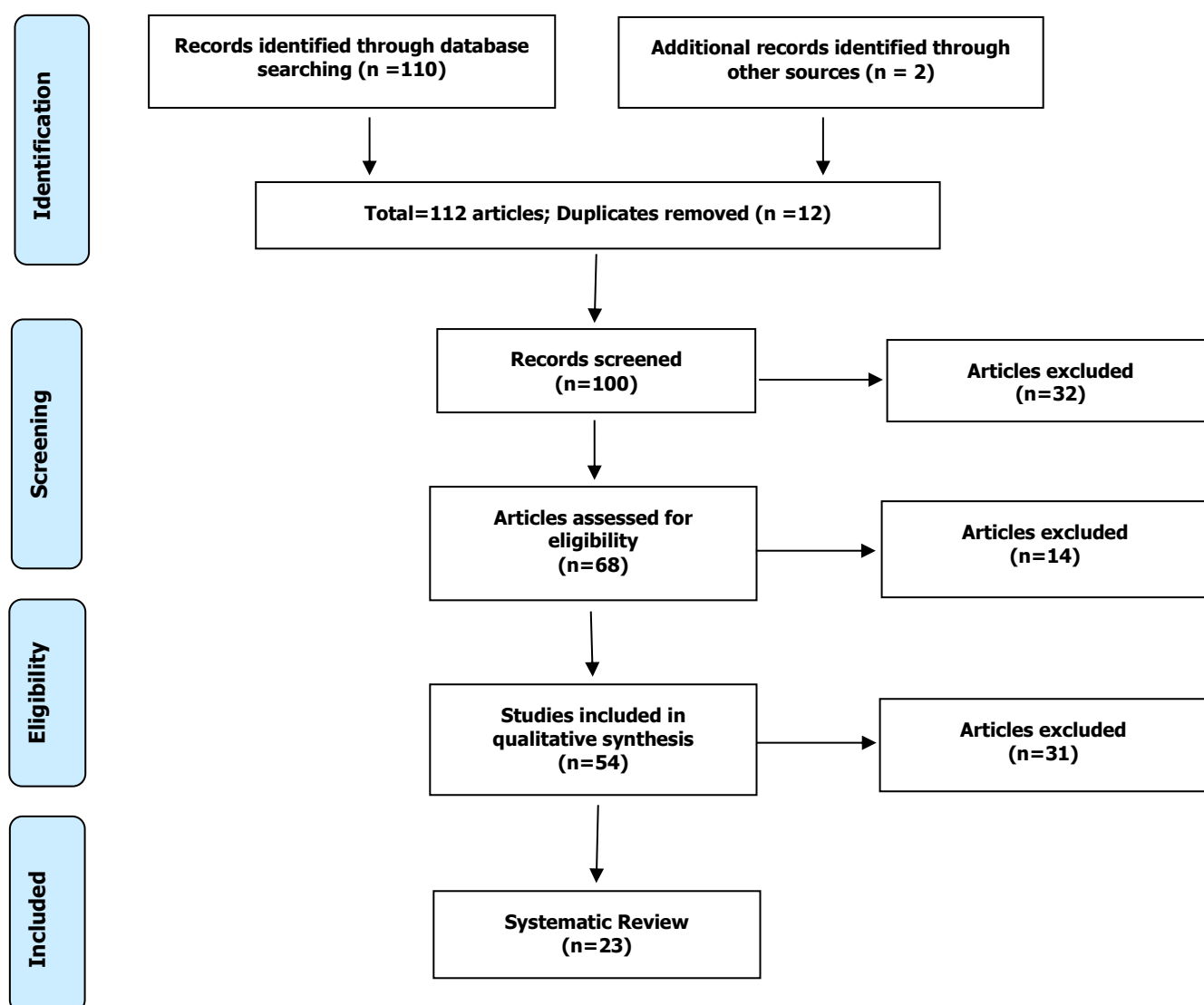
A total of 112 articles were found on bone regeneration and implantology. Initially, duplication of articles was excluded. After this process, the abstracts were evaluated and a new exclusion was performed, removing the articles that did not address the theme of this article. In total, 54 articles were fully evaluated and 23 were included and evaluated in this study (Figure 1).

Considering the Cochrane tool for risk of bias, the overall assessment in 4 studies with a high risk of bias and 2 studies with uncertain risk. The domains that presented the highest risk of bias were related to the number of participants in each study approached, and the uncertain risk was related to the safety and efficacy of bone regeneration and implantology. Also, there was no funding source in 3 studies and 2 studies did not disclose information about the declaration of conflict of

interest.

After the complete analysis of the studies that were listed to compose this systematic review, it was found that the lack of bone in the alveolar crests has been a major problem in the functional esthetic recovery in patients who suffered dentoalveolar trauma, traumatic tooth extractions, congenital tooth absence, maxillary and mandibular pathologies, in addition to infections due to the emotional and the possibility of deformity and also the economic impact they cause on the National Health System (NHS) [1,2]. Furthermore, bone loss can also occur due to periodontal disease, traumatic surgery or even for physiological reasons due to lack of adequate or inadequate prosthetic load [3]. Trauma in the face region can affect both soft tissue and hard tissue, so these injuries can affect the quality of life and health of the victim [3].

**Figure 1.** Eligibility.



Maxillofacial trauma can be considered one of the most devastating aggressions found in traumatology and oncology due to the emotional consequences and the possibility of deformity, as well as the economic impact they cause on the Unified Health System (NHS) [4]. The face, more than any other region of the body, is affected by aesthetic changes as it is always visible and damage is immediately noticed. For this reason, facial trauma deserves attention in the treatment of multiple trauma due to its high incidence and severity [13].

In this context, implant dentistry stands out as a modern method of oral rehabilitation for totally or partially edentulous patients. For this method to develop properly, bone integration of the implant into the recipient bone tissue must occur, since bone integration is the key to clinical surgical success, which will be completed after the end of the prosthetic phase [14]. Dental implants are being used more and more due to the high success rates. However, a large number of patients do not have sufficient minimum bone conditions for the installation of implants, therefore, previous bone reconstructive surgery is necessary. It is essential that dentists master the knowledge in the healing process of post-extraction alveoli, in order to provide correct planning of cases [1].

In this context, fibrin-rich plasma (FRP) as an autologous biomaterial was developed in France by Choukroun et al. (1993) [4] for specific use in oral and maxillofacial surgery. This biomaterial has the majority of leukocytes, platelets, and growth factors, forming a fibrin matrix, with a three-dimensional architecture. It is the second generation of platelet concentrate with a high potential for wound repair.

Furthermore, FRP is based on protecting growth factors from proteolysis that can maintain their activity for a longer period and stimulate bone regeneration more efficiently [15]. The most critical phase of the sinus membrane elevation procedure after maxillary sinus lateral wall osteotomy is its detachment [16]. At this stage, Schneider's membrane ruptures may occur, in around 15.0% of the cases, which, depending on the size of the perforation, may make the graft unfeasible, mainly due to the containment character of the graft material that the membrane exerts. The most frequent causes of these perforations are inadequate osteotomies, incomplete membrane detachments with lack of bone support for lifting currettes, exerting excessive pressure on the membrane, and the presence of septa [17-20].

If sinus membrane perforations are present, this should be quantified [21], as small perforations do not require treatment as membrane folds obliterate the

perforation. In the case of ruptures greater than 5.0 mm, the use of collagen membranes is indicated [22]. Another study indicated the use of fibrin membranes obtained from FRP to seal the perforations. In the presence of perforations larger than 10.0 mm, the surgery should be aborted and re-entry performed after 60 to 90 days [23].

The development of optimized implant surfaces is a matter of great research with the objective of accelerating the osseointegration process, leading to a reduction in the waiting time before loading, in addition to making the immediate loading of the implant safer [23]. It was documented for the first time that the combination of biomaterial and FRP significantly improved bone regeneration in the peri-implant area. The placement of the implant with the simultaneous use of the PRP creates a good relationship between the hard tissue and the soft tissue, in addition to the advantage of the psychological relationship with the patient [24].

The most used xenograft in guided bone regeneration procedures is deproteinized bovine bone mineral, commercially known as Bio-Oss®, it is the most researched product in regenerative dentistry worldwide. It is a bone of bovine origin processed to produce natural bone minerals without organic elements. After thermal and chemical treatments, the inorganic phase of bovine bone consists mainly of hydroxyapatite (HA) which retains the porous architecture. The excellent osteoconductive properties of Bio-Oss® lead to predictable and efficient bone regeneration, Bio-Oss® particles become an integral part of the newly formed bone structure and conserve their volume in the long term [9]. Due to its 'great' resemblance to the human bone, the Bio Oss® is 'incorporated' into the 'natural process of 'shaping' and 'reshaping'. The highly porous structure of the Bio Oss® offers a lot of space for the formation of blood vessels (angiogenesis) and the deposit of neoformed bone [25]. The microstructure of the surface of Bio Oss® helps the excellent growth of the osteoblasts which are responsible for bone formation [24].

Thus, fibrin-rich plasma (FRP) as an autologous biomaterial for use in oral and maxillofacial surgery presents the majority of leukocytes, platelets, and growth factors, forming a fibrin matrix, with a three-dimensional architecture. The Bio-Oss® (Geistlich) biomaterial, as it is biodegradable, biocompatible, non-toxic, and has low immunogenicity and bio stimulators, can act in the regeneration of bone tissue, as it establishes with the adenomatous mesenchymal stem cells the appropriate biological niche for bone growth and, thus, allowing the dental implant as effectively as possible [26].

Based on this, two important studies reported results on the combined use of Bio-Oss® and FRP. Thus, the first

study investigated clinically and histologically the potential of FRP as a graft material in pre-implant reconstructive surgeries for severe maxillary atrophy after sinus elevation procedures in 106-120-180 days, to determine whether the use of FRP is able to accelerate the bone regeneration process, which is essential to promote implant stability. This study also includes a control group, in which only deproteinized bovine bone (Bio-Oss®) was used as reconstructive material. As a result, in fact, the use of FRP optimized bone formation [8].

The second study compared the use of Bio-Oss® mixed with FRP and Bio-Oss® with Tisseel® to improve bone regeneration. After elevating the sinus membrane in both maxillary sinus cavities, an implant was placed in the sinus cavity. In one of the sinus cavities, the FRP/Bio-Oss® composite was grafted and the Tisseel® / Bio-Oss® composite was grafted in the other sinus cavity. After a 6-month healing period, bone formation at the graft sites and bone-implant contact were assessed. The mean rate of osseointegration was  $43.5 \pm 12.4\%$  and the rate of new bone formation was  $41.8 \pm 5.9\%$  at the FRP/Bio-Oss® composite sites. In the composite sites, Tisseel® / Bio-Oss® was  $30.7 \pm 7.9\%$  and  $31.3 \pm 6.4\%$ . There were statistically significant differences between groups. The findings of this study suggested that when FRP is used as an adjuvant to Bio-Oss® particles for bone augmentation in the maxillary sinus, bone formation at the graft sites is significantly greater than when Tisseel® is used [9].

For the success of dental implant practice, osseointegration is essential. However, it is a complex process with many factors interfering in the formation and maintenance of bone tissue around the implant, such as topography and surface roughness, biocompatibility, and loading conditions. In addition, it is necessary for a host bone layer that is healthy, compatible, and that allows primary stability [22].

In this sense, after an extraction, the repair process occurs in the inner region of the alveolus, together with the formation of a clot rich in cells and growth factors, promoting neoformation, bone remodeling, and soft tissue epithelialization [21]. During this process, the alveolar ridge undergoes relevant changes, both in height and in thickness, which influence the possibility of installing the implants. Thus, the optimized processes of implantology and biomaterials allow the installation of implants in areas of thin bone thickness, width, and height, with simpler surgeries and greater success rate and patient comfort [21].

The lack of bone in the alveolar crests has been a major problem in functional aesthetic recovery in patients who have suffered dentoalveolar trauma,

traumatic tooth extractions, congenital tooth loss, maxillary and mandibular pathologies. To fill large bone defects, the development of bone regeneration improves the epithelial barriers for the bone graft, favoring greater predictability in alveolar and peri-implant reconstructions, with a good prognosis. In this sense, filling biomaterials can be fibrin-rich plasma (FRP), Bio-Oss®, hydroxyapatite, lyophilized and ground demineralized bone marrow, autogenous bone, which is considered the gold standard, among others [21].

To improve osseointegration and bone anchorage, surface modifications can be chemical, such as calcium phosphate (Ca-P) or physical impregnation, being related to the microtopography of the implant [24]. Several variables affect the biological activity of FRP preparations, such as the number of centrifuges used, the centrifugation speed, and other protocols that result in preparations with multiple volumes, platelet numbers, amount of growth factors, and concentration of white blood cells and fundamental erythrocytes [22].

Some researchers recommend avoiding tissue exposure to FRP-containing leukocytes, arguing that an inflammatory reaction may occur. On the other hand, other authors have described beneficial effects due to increased immunological and antibacterial resistance, although there is no clinical evidence to support its effect [23]. FRP has gained prominence in the scientific community for not requiring the addition of an activator or anticoagulant, making the product more autologous, featuring a fibrin network that protects the growth factors, keeping them in place for longer. It also shows other forms of application making its use simpler [24].

In this sense, the bioactivation of the dental implant surface with FRP has been described and discussed by the scientific community as a surface treatment for the stimulation and acceleration of the osseointegration process, as well as to achieve greater primary implant stability [23]. The need to rehabilitate edentulous areas that have undergone major resorptions is a current need and the maxillary sinus elevation maneuver is a viable way to implant an anchorage for implant-supported oral rehabilitation [1]. One of the relatively frequent complications (15.0%) of the procedures is the rupture of the sinus membrane during the displacement of the sinus membrane. The main complication of this rupture is related to the containment of the graft [1].

In this context, small perforations with an extension of 1.0 to 2.0 mm are contoured with the membrane folds in their elevation, but when they reach lengths greater than these, the membranes must be added to close the same, and larger tears than 10.0 mm. The surgery must be aborted and reinserted after a period of re-epithelialization of the antral cavity, that is, between 60



and 90 days [2].

Thus, the use of an autologous fibrin membrane, obtained by centrifugation of the patient's venous blood, without adding anticoagulants, provides a quick and efficient repair of surgical wounds. Fibrin gel constitutes the first scar matrix of the injured sites [3]. FRP is the second generation of fibrin concentrates, succeeding FRP that had as a limitation the release of growth factors and cytokines in a very short time [4].

FRP presents progressive polymerization and the incorporation of circulating cytokines increases in the fibrin mesh. This configuration implies a longer life for these cytokines, as they are released and used only in the remodeling of the initial scar matrix. Cytokines are thus kept available in situ for a convenient period when cells begin to heal the matrix, that is, when they need to be stimulated to reconstruct the injured site [5]. According to some authors, FRP acts to protect growth factors from proteolysis, which, in this way, can maintain their activity for a longer period and stimulate tissue regeneration. The use of autogenous bone, especially the bone induction capacity, has been recommended for filling the antral cavity [6].

## Conclusion

Based on the literary findings, it became evident that FRP is favorable for bone formation processes for dental implants, especially when combined with Bio-Oss®.

## References

1. Abdel-Kader, M.A., Abdelazeem, A.F., Ahmed, N.E.B., Khalil, Y.M., Mostafa, M.I. Oral rehabilitation of a case with regional odontodysplasia using a regenerative approach-A case report and a review of literature. *Spec Care Dentist*. 2019, May;39(3):330-339. doi: 10.1111/scd.12378. Epub 2019 Apr 16.
2. Arab, H., Shiezadeh, F., Moeintaghavi, A., Anbiaei, N., Mohamadi, S. Comparison of Two Regenerative Surgical Treatments for Peri-Implantitis Defect using Natix Alone or in Combination with Bio-Oss and Collagen Membrane. *J Long Term Eff Med Implants*. 2016;26(3):199-204. doi: 10.1615/JLongTermEffMedImplants.2016016396.
3. Chiapasco M., Casentini P., Zaniboni M. Bone augmentation procedures in implant dentistry. *Int J Oral Maxillofac Implants*. 2009;24 Suppl: 237-59.
4. Choukroun J, Diss A., Simonpieri A, Girard M.O. Schhoeffler C., Dohan S.L., et al. Platelet-rich-fibrin (PRF): a second generation platelet concentrate. Part IV: clinical effects on tissue healing. *Oral Surg. Oral Med. Oral Pathol. Oral Radiol. Endod* 2006; 101 (3): e 56 – 60.
5. Diana, C., Mohanty, S., Chaudhary, Z., Kumari, S., Dabas, J., Bodh, R. Does platelet-rich fibrin have a role in osseointegration of immediate implants? A randomized, single-blind, controlled clinical trial. *Int J Oral Maxillofac Surg*. 2018 Sep;47(9):1178-1188. doi: 10.1016/j.ijom.2018.01.001. Epub 2018 May 7.
6. Canellas JVDS, Drugos L, Ritto FG, Fischer RG, Medeiros PJD. Xenograft materials in maxillary sinus floor elevation surgery: a systematic review with network meta-analyses. *Br J Oral Maxillofac Surg*. 2021 Feb 23:S0266-4356(21)00075-9. doi: 10.1016/j.bjoms.2021.02.009. Epub ahead of print. PMID: 34120778.
7. Kyyak S, Blatt S, Schiegnitz E, Heimes D, Staedt H, Thiem DGE, Sagheb K, Al-Nawas B, Kämmerer PW. Activation of Human Osteoblasts via Different Bovine Bone Substitute Materials With and Without Injectable Platelet Rich Fibrin in vitro. *Front Bioeng Biotechnol*. 2021 Feb 17;9:599224. doi: 10.3389/fbioe.2021.599224. PMID: 33681155; PMCID: PMC7925396.
8. Shen MH, Huang YL, Li Z, Zhang YD, He YP, Wang L. [Effect of platelet rich fibrin combining with Bio-oss to treat furcation involvement]. *Shanghai Kou Qiang Yi Xue*. 2018 Oct;27(5):508-512. Chinese. PMID: 30680396.
9. Xuan F, Lee CU, Son JS, Jeong SM, Choi BH. A comparative study of the regenerative effect of sinus bone grafting with platelet-rich fibrin-mixed Bio-Oss® and commercial fibrin-mixed Bio-Oss®: an experimental study. *J Craniomaxillofac Surg*. 2014 Jun;42(4):e47-50 doi: 10.1016/j.jcms.2013.05.029. Epub 2013 Aug 2].
10. The PRISMA 2020 statement: an updated guideline for reporting systematic reviews. *BMJ* 2021; 372 doi: https://doi.org/10.1136/bmj.n71
11. H Balshem H, Grade guidelines: 3 rating the quality of evidence. *Journal of Clinical Epidemiology*, Maryland Heights, 64 (4) (2011) 401-406.
12. Higgins, S Green, *Cochrane Handbook for Systematic Reviews of Interventions*. Version

- 5.1.0 [updated March 2011]. The Cochrane Collaboration; 2011.
13. Neto, R.M.S., Zotarelli-Filho, I.J. & Ribeiro da Silva, C.E.X.S. Meta-analysis of the Major Clinical Results of the Treatment with 1-Point Fixation in Fractures in the Zygomatic-Maxillary Complex: Success Rate and Complications. *J. Maxillofac. Oral Surg.* (2021). <https://doi.org/10.1007/s12663-021-01603-3>
  14. Fang J, Xin XR, Li W, Wang HC, Lv HX, Zhou YM. Immediate implant placement in combination with platelet rich-fibrin into extraction sites with periapical infection in the esthetic zone: A case report and review of literature. *World J Clin Cases.* 2021 Feb 6;9(4):960-969. doi: 10.12998/wjcc.v9.i4.960. PMID: 33585645; PMCID: PMC7852644.
  15. Starch-Jensen, T., Aludden, H., Hallman, M., Dahlin, C., Christensen, A.E., Mordenfeld, A. A systematic review and meta-analysis of long-term studies (five or more years) assessing maxillary sinus floor augmentation. *Int J Oral Maxillofac Surg.* 2018 Jan;47(1):103-116. doi: 10.1016/j.ijom.2017.05.001. Epub 2017 May 22.
  16. Strauss, F.J., Stähli, A., Gruber, R. The use of platelet-rich fibrin to enhance the outcomes of implant therapy: A systematic review. *Clin Oral Implants Res.* 2018 Oct;29 Suppl 18:6-19. doi: 10.1111/clr.13275.
  17. Tajima, N., Ohba, S., Sawase, T., Asahima, I. Evaluation of sinus floor augmentation with simultaneous implant placement using platelet-rich-fibrin as sole grafting material. *Int J Oral Maxillofac Implants* 2013;28(1):77-83.
  18. Tatullo, M., Marrelli, M., Cassetta, M., Pacifici, A., Stefanelli, L.V., Scacco, S., Dipalma, G., Pacifici, L., Inchingolo, F. Platelet Rich Fibrin (PRF) in reconstructive surgery of atrophied maxillary bones: clinical and histological evaluations. *Int J Med Sci.* 2012;9(10):872-80 [doi: 10.7150/ijms.5119. Epub 2012 Nov 7].
  19. Wu, I.H., Bakhshalian, N., Galaustian, R., Naini, R.B., Min, S., Freire, M., Zadeh, H.H. Retrospective Analysis of the Outcome of Ridge Preservation with Anorganic Bovine Bone Mineral: Marginal Bone Level at Implants Placed Following Healing of Grafted Extraction Sockets. *Int J Periodontics Restorative Dent.* 2019 Jan/Feb;39(1):131-140. doi: 10.11607/prd.3308.
  20. Xuan, F., Lee, C.U., Son, J.S., Jeong, S.M., Choi, B.H. A comparative study of the regenerative effect of sinus bone grafting with platelet-rich fibrin-mixed Bio-Oss® and commercial fibrin-mixed Bio-Oss®: an experimental study. *J Craniomaxillofac Surg.* 2014 Jun;42(4):e47-50 [ doi: 10.1016/j.jcms.2013.05.029. Epub 2013 Aug 2].
  21. You, J.S., Kim, S.G., Oh, J.S., Kim, J.S. Effects of Platelet-Derived Material (Platelet-Rich Fibrin) on Bone Regeneration. *Implant Dent.* 2019 Mar 8 [doi: 10.1097/ID.0000000000000877.
  22. Zhang Y, Tangl S, Huber CD, Lin Y, Qiu L, Raush-Fan X. Effects of Choukroun's platelet-rich-fibrin on bone regeneration in combination with deproteinized bovine bone mineral in maxillary sinus augmentation: a histological and histomorphometric study. *J Craniomaxillofac Surg.* 2012; 40 (4): 321 -8.
  23. Zhou J, Li X, Sun X, Qi M, Chi M, Yin L, Zhou Y. Bone regeneration around immediate placed implant of molar teeth with autologous platelet-rich fibrin: Two case reports. *Medicine (Baltimore).* 2018 Nov;97(44):e13058. doi: 10.1097/MD.00000000000013058.
  24. Kempraj J, Sundaram SS, Doss GPT, Nakeeran KP, Raja VBKK. Maxillary Sinus Augmentation Using Xenograft and Choukroun's Platelet-Rich Fibrin as Grafting Material: A Radiological Study. *J Maxillofac Oral Surg.* 2020 Jun;19(2):263-268. doi: 10.1007/s12663-019-01197-x. Epub 2019 Feb 26. PMID: 32346238; PMCID: PMC7176753.
  25. Li P, Zhu H, Huang D. Autogenous DDM versus Bio-Oss granules in GBR for immediate implantation in periodontal postextraction sites: A prospective clinical study. *Clin Implant Dent Relat Res.* 2018 Dec;20(6):923-928. doi: 10.1111/cid.12667. Epub 2018 Sep 19.
  26. Moreira AC, Silva JR, Samico RP, Nishioka GNM, Nishioka RS. Application of Bio-Oss in tissue regenerative treatment prior to implant installation: literature review. *Braz Dent Sci.* 22(2), 2019.

### **Acknowledgement**

Nil.

### **Funding**

Not applicable.

### **Data sharing statement**

No additional data are available.

### **Conflict of interest**

The authors declare no conflict of interest.

### **About the license**

© The author(s) 2021. The text of this article is open access and licensed under a Creative Commons Attribution 4.0 International License.





