



Major considerations of common and zygomatic implants in patients using bisphosphonates and the risk of osteonecrosis: a concise systematic review

Anna Laura Bergamo Volpe^{1,*}, Leandro Cusinato Faria¹, Fabio Alarcon Idalgo¹,
Alvaro José Cicareli¹

¹ UNORTE - University Center of Northern São Paulo - Dentistry - Department of Implant Dentistry, Sao Jose do Rio Preto, Sao Paulo, Brazil.

*Corresponding author: Anna Laura Bergamo Volpe.
UNORTE - University Center of Northern São Paulo -
Dentistry - Department of Implant Dentistry,
Sao Jose do Rio Preto, Sao Paulo, Brazil.

E-mail: anna_laura.b@hotmail.com

DOI: <https://doi.org/10.54448/mdnt26101>

Received: 11-10-2025; Revised: 01-11-2026; Accepted: 01-12-2026; Published: 01-15-2026; MedNEXT-id: e26101

Editor: Dr. Sanjeev Ariyandath Sreenivasan, MD MCh.

Abstract

Introduction: In the context of dental implants and bone strengthening, bisphosphonates (BPs) are antiresorptive agents. However, prolonged use of BPs may increase the risk of medication-related osteonecrosis of the jaw (MRONJ), impairing the placement of common and zygomatic implants.

Objective: This study aimed to analyze the major considerations of common and zygomatic implants in patients using bisphosphonates, as well as the risk of osteonecrosis. **Methods:** The systematic review rules of the PRISMA Platform were followed. The search was conducted from September to October 2025 in the Web of Science, Scopus, Embase, PubMed, Science Direct, SciELO, and Google Scholar databases. The quality of the studies was based on the GRADE instrument, and the risk of bias was analyzed according to the Cochrane instrument. **Results and Conclusion:** According to the GRADE instrument, most studies presented homogeneity in their results, with $X^2=81.2\%>50\%$. A total of 81 articles were found and submitted for eligibility analysis, with 07 final studies selected to compose the results of this systematic review. Considering the Cochrane tool for risk of bias, the overall assessment resulted in 27 studies with a high risk of bias and 22 studies that did not meet GRADE and AMSTAR-2. It was concluded that current evidence does not suggest a strong association between antiresorptive therapy in patients with osteoporosis and failure of common and zygomatic dental implants. Low-certainty evidence suggests that antiresorptive

treatment for osteoporosis reduces dental implant failure. Bisphosphonates are associated with medication-related osteonecrosis of the jaw in patients with osteoporosis receiving dental implants, with moderate certainty.

Keywords: Bisphosphonates. Antiresorptive agents. Osteonecrosis. Implants. Zygomatic implant.

Introduction

In the context of dental implants and bone strengthening, bisphosphonates (BPs) are antiresorptive agents used in the treatment of osteoporosis and other conditions that present with bone fragility. BPs act by inhibiting the resorption of trabecular bone by osteoclasts, stimulating apoptosis of these cells, and progressively reducing physiological bone remodeling. In addition, they have antiangiogenic effects. As a result of BP use, bone becomes more fragile, and its repair capacity decreases [1-3].

Indications for BP therapy include osteoporosis and cancer patients for the prevention of bone metastases. The most important therapeutic action of bisphosphonates is the inhibition of bone resorption, which begins 1 to 2 days after administration. However, prolonged use of BPs increases the risk of medication-related osteonecrosis of the jaw (MRONJ) [4-7].

MRONJ is related to progressive bone destruction in the maxillofacial region, which may be accompanied by pain, paresthesia, edema, soft tissue ulceration, suppuration, and intra/extraoral fistulas. Oral

rehabilitation with conventional dental implants is not indicated in patients with MRONJ due to the risk of creating a new necrotic area [1-4].

The mandible and maxilla are the regions most commonly affected by MRONJ [6]. Although the etiology of MRONJ has not yet been fully elucidated, the most accepted theory is that the maxillary bone exhibits greater bone remodeling compared to other regions of the skeleton [3,5,7]. An alternative bone site for implant anchorage for dental prosthesis fixation, such as the zygomatic region, may be an alternative for these patients, aiming to improve quality of life in functional terms.

In this sense, the placement of zygomatic implants (ZI) in patients with severely atrophic maxilla for oral rehabilitation is considered a successful treatment modality in patients with edentulous atrophic maxilla to improve function and aesthetics. However, the placement of ZI is still debated in patients who use bisphosphonates or have a history of using these medications [2].

Therefore, this concise systematic review study aimed to analyze the major considerations of common and zygomatic implants in patients using bisphosphonates and the risk of osteonecrosis.

Methods

Study Design

This study followed the international systematic review model, following the PRISMA (preferred reporting items for systematic reviews and meta-analysis) rules. Available at: <http://www.prisma-statement.org/?AspxAutoDetectCookieSupport=1>. Accessed at: 10/20/2025. The AMSTAR 2 (Assessing the methodological quality of systematic reviews) methodological quality standards were also followed. Available at: <https://amstar.ca/>. Accessed at: 10/20/2025.

Search Strategy and Search Sources

The literature search process was carried out from September to October 2025 and developed based on Web of Science, Embase, Scopus, PubMed, Lilacs, Ebsco, Scielo, and Google Scholar, covering scientific articles from various periods to the present day. The following descriptors were used in health sciences (DeCS/MeSH terms): "*Bisphosphonates. Antiresorptive agents. Osteonecrosis. Implants. Zygomatic implant*", and the Boolean "and" was used between the MeSH terms and "or" between the historical findings.

Study Quality and Risk of Bias

Quality was classified as high, moderate, low, or very low regarding the risk of bias, clarity of

comparisons, precision, and consistency of analyses. The most evident emphasis was on systematic review articles or meta-analyses of randomized clinical trials, followed by randomized clinical trials. Low quality of evidence was attributed to case reports, editorials, and brief communications, according to the GRADE instrument. The risk of bias was analyzed according to the Cochrane instrument by analyzing the Funnel Plot graph (Sample size versus Effect size), using Cohen's test (d).

Summary of Findings

A total of 81 articles were found and submitted to eligibility analysis, with 07 final studies selected to compose the results of this systematic review. The listed studies were of medium to high quality (Figure 1), considering the level of scientific evidence of studies such as meta-analysis, consensus, randomized clinical, prospective, and observational. Biases did not compromise the scientific basis of the studies. According to the GRADE instrument, most studies presented homogeneity in their results, with $X^2=81.2\%>50\%$. Considering the Cochrane tool for risk of bias, the overall assessment resulted in 27 studies with a high risk of bias and 22 studies that did not meet GRADE and AMSTAR-2.

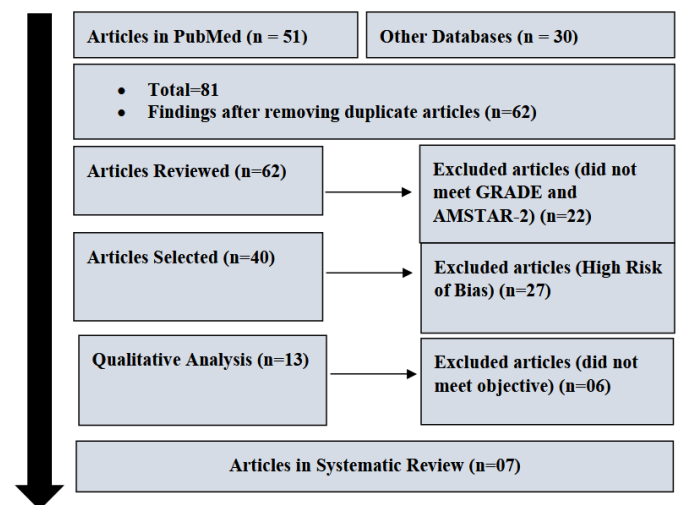


Figure 1. Flowchart showing the article selection process. Source: Own Authorship.

Figure 2 presents the results of the risk of bias of the studies using the Funnel Plot, showing the calculation of the Effect Size (Magnitude of the difference) using Cohen's Test (d). Precision (sample size) was determined indirectly by the inverse of the standard error (1/Standard Error). This graph had a symmetrical behavior, not suggesting a significant risk of bias, both among studies with small sample sizes (lower precision) that are shown at the base of the graph and in studies with large sample sizes that are presented at the top.

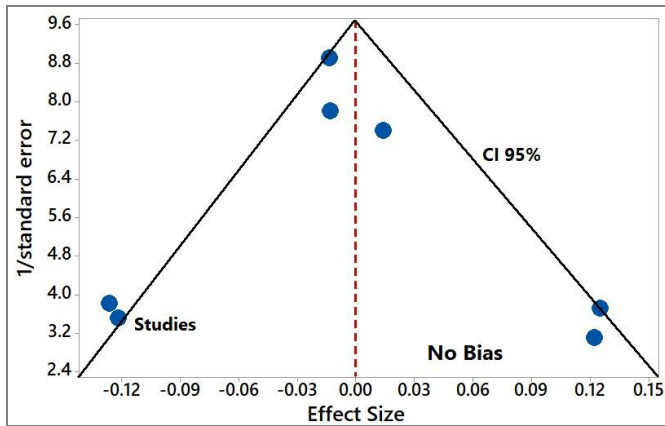


Figure 2. The symmetrical funnel plot suggests no risk of bias among the studies with small sample sizes that are shown at the bottom of the graph. High confidence and high recommendation studies are shown above the graph (n=07 studies). Source: Own Authorship.

Major Results

A case study described the oral rehabilitation of a 78-year-old patient who developed an osteonecrotic lesion in the fourth year of treatment with bisphosphonates. The patient underwent a series of surgeries, including resection of necrotic tissue in the right maxillary region and removal of conventional implants. The patient had a large maxillary defect, and no other treatment modality, such as conventional prostheses and traditional dental implants, was applicable. The patient had a very low quality of life, and as a rehabilitation option, two zygomatic implants (ZI) were planned and performed as anchorage for a maxillary fixed prosthesis. Radiographic and clinical examination after three years of follow-up indicated that healing was achieved and that healthy tissue had formed around the ZI. The patient did not present new necrotic tissue or other complications in the oral cavity. ZI after resective surgery can be considered a promising alternative for patients with MRONJ with large defects, when other treatment alternatives fail or are not applicable [8].

Osseointegration is the fundamental mechanism that facilitates the direct binding between implants and bone tissue. However, bisphosphonates inhibit mitochondrial ADP/ATP translocase through an interaction with aminoacyl-tRNA class II synthase, leading to osteoclast apoptosis, as well as inhibiting the prenylation of small GTPases, disrupting cytoskeletal integrity and vesicular transport, ultimately resulting in osteoclast apoptosis. In osteoblasts, low concentrations of bisphosphonates promote bone differentiation and formation, while high concentrations inhibit bone metabolism. Animal experiments and clinical studies have demonstrated that the local application of bisphosphonates, such as through implant coatings, significantly increases the resistance to osseointegration

and reduces marginal bone resorption. Furthermore, synergistic effects can be achieved when bisphosphonates are combined with parathyroid hormone or basic fibroblast growth factor.

However, prolonged systemic use of bisphosphonates, particularly intravenously, can inhibit bone remodeling [1,9].

The authors Ali et al. (2025) [10] developed a systematic review study to analyze whether placing dental implants in patients on antiresorptive therapy increases the risk of MRONJ and/or impacts implant survival. In patients with osteoporosis on antiresorptive therapy, the Working Group suggests that antiresorptive therapy does not need to be interrupted before dental implant placement (weak recommendation, very low-quality evidence). Prolonged use of bisphosphonates may be associated with a small increased risk of MRONJ (3 cases per 1000 patients; adjusted hazard ratio: 4.09, 95% CI: 2.75-6.09, $p < 0.001$, moderate certainty). Implants can be safely placed in the presence of concomitant use of bisphosphonates or denosumab in patients with osteoporosis, without evidence of increased risk of implant failure/impairment.

Furthermore, the authors Lin et al. (2025) [11] evaluated the effects of bisphosphonates (BP) and denosumab on dental implants, including implant failure (IF), marginal bone loss (MBL), and MRONJ. A total of 21 studies were included. BP use was associated with IF only at the implant level (RR 1.74; 95% CI: 1.10-2.75), but not at the patient level (RR 1.01; 95% CI: 0.35-2.91). Analysis of two studies did not indicate a significant correlation between bisphosphonate (BP) use and marginal bone loss (MBL) (MD 0.05; 95% CI: -0.12 to 0.21). The use of BP was associated with MRONJ (RR 3.45; 95% CI: 2.56-4.65), while denosumab did not show a statistically significant correlation with MRONJ (RR 25.98; 95% CI: 0.31-2165.63).

Moreover, the authors Mirza et al. (2025) [12] performed a systematic review and meta-analysis to analyze dental implant failure and MRONJ associated with antiresorptive therapy for osteoporosis. Nine studies (n = 655) were included in the implant failure analysis. The random-effects meta-analysis revealed wide confidence intervals (CI) for implant failure among those exposed to antiresorptives (relative risk, 0.82; 95% CI, 0.52-1.28; $p = 0.38$, very low certainty). Implant-level sensitivity analysis suggested that antiresorptive agents reduce implant failure (relative risk, 0.53; 95% CI, 0.34-0.81; $p = 0.003$, very low certainty). 186 cases of MRONJ were identified in implant recipients. The pooled rate of MRONJ after implantation in individuals exposed to antiresorptive therapy was 0.5%, considering 21 cohorts. A single

risk-adjusted MRONJ study found that bisphosphonates increased the incidence of MRONJ by 3 cases per 1000 patients (adjusted hazard ratio, 4.09; 95% CI, 2.75-6.09; $p < 0.001$, moderate certainty).

Finally, a clinical case showed the occurrence of severe osteonecrosis related to bisphosphonates, associated with periodontitis and the removal of dental implants in an osteoporotic patient treated with oral bisphosphonates for an uninterrupted period of 15 years [13].

Conclusion

It was concluded that current evidence does not suggest a strong association between antiresorptive therapy in patients with osteoporosis and failure of common and zygomatic dental implants. Low-certainty evidence suggests that antiresorptive treatment for osteoporosis reduces dental implant failure. Bisphosphonates are associated with medication-related osteonecrosis of the jaw in patients with osteoporosis receiving dental implants, with moderate certainty.

CRedit

Author contributions: **Conceptualization**- Anna Laura Bergamo Volpe, Leandro Cusinato Faria, Fabio Alarcon Idalgo, Alvaro José Cicareli; **Investigation**- Anna Laura Bergamo Volpe, Leandro Cusinato Faria; **Methodology**- Anna Laura Bergamo Volpe, Leandro Cusinato Faria; **Project administration**- Anna Laura Bergamo Volpe, Leandro Cusinato Faria, Fabio Alarcon Idalgo, Alvaro José Cicareli; **Supervision**- Fabio Alarcon Idalgo, Alvaro José Cicareli; **Writing - original draft**- Anna Laura Bergamo Volpe, Leandro Cusinato Faria, Fabio Alarcon Idalgo, Alvaro José Cicareli; **Writing - review & editing**- Anna Laura Bergamo Volpe, Leandro Cusinato Faria, Fabio Alarcon Idalgo, Alvaro José Cicareli.

Acknowledgment

Not applicable.

Ethical Approval

Not applicable.

Informed Consent

Not applicable.

Funding

Not applicable.

Data Sharing Statement

No additional data are available.

Conflict of Interest

The authors declare no conflict of interest.

Similarity Check

It was applied by Ithenticate®.

Application of Artificial Intelligence (AI)

Not applicable.

Peer Review Process

It was performed.

About The License©

The author(s) 2026. The text of this article is open access and licensed under a Creative Commons Attribution 4.0 International License.

References

1. Jawad N, Burns M, Patel V. A literature review and update on medications related to osteonecrosis of the jaw independent of bisphosphonates and denosumab. *Br Dent J.* 2025 Nov;239(9):613-619. doi: 10.1038/s41415-025-8643-1.
2. Grecchi F, Bianchi AE, Siervo S, Grecchi E, Lauritano D, Carinci F. A new surgical and technical approach in zygomatic implantology. *Oral Implantol.* 2017;10:197– 208. doi: 10.11138/orl/2017.10.2.197.
3. Nogueira D, Caldas IM, Dinis-Oliveira RJ. Bisphosphonates and osteonecrosis of the jaws: Clinical and forensic aspects. *Arch Oral Biol.* 2023 Nov;155:105792. doi: 10.1016/j.archoralbio.2023.105792.
4. Park JH, Kong SH, Lee J, Oh J, Lee JR, Lee HJ, Kim JW. Time since last intravenous bisphosphonate and risk of osteonecrosis of the jaw in osteoporotic patients. *Nat Commun.* 2025 May 11;16(1):4367. doi: 10.1038/s41467-025-59718-x.
5. Storelli S, Palandrani G, Dondi C, Tagliatesta L, Rossi A. Severe Case of Osteonecrosis Following Implant Placement in a Patient in Therapy With Bisphosphonates: A Case Report. *J Oral Implantol.* 2019 Apr;45(2):139-144. doi: 10.1563/aaid-joi-D-17-00309.
6. Tam Y, Kar K, Nowzari H, Cha HS, Ahn KM. Osteonecrosis of the jaw after implant surgery in patients treated with bisphosphonates--a presentation of six consecutive cases. *Clin Implant Dent Relat Res.* 2014 Oct;16(5):751-61.

- doi: 10.1111/cid.12048.
7. Kanwar N, Bakr MM, Meer M, Siddiqi A. Emerging therapies with potential risks of medicine-related osteonecrosis of the jaw: a review of the literature. *Br Dent J.* 2020 Jun;228(11):886-892. doi: 10.1038/s41415-020-1642-3.
 8. Goker F, Grecchi E, Del Fabbro M, Longoni S, Stefanelli LV, Grecchi F. Zygomatic Implant Insertion in MRONJ: A Case Report with a Follow-Up of 3 Years. *J Clin Med.* 2023 May 5;12(9):3300. doi: 10.3390/jcm12093300.
 9. Liu H, Wang X, Shi Y, Yang Y, Li P, Chen Q, Hu Y, Wang J, Gu B. Dual effects of bisphosphonates on bone metabolism and implant osseointegration: mechanisms, risks and clinical strategies. *J Stomatol Oral Maxillofac Surg.* 2025 Dec;126(6S):102534. doi: 10.1016/j.jormas.2025.102534.
 10. Ali DS, Khan AA, Morrison A, Tetradis S, Mirza RD, El Rabbany M, Abrahamsen B, Aghaloo TL, Al-Alwani H, Al-Dabagh R, Anastasilakis AD, Bhandari M, Body JJ, Brandi ML, Brignardello-Petersen R, Brown JP, Cheung AM, Compston J, Cooper C, Diez-Perez A, Ferrari SL, Guyatt G, Hanley D, Harvey NC, Josse RG, Kendler DL, Khan S, Kim S, Langdahl BL, Magopoulos C, Masri BK, Morgan SL, Morin SN, Napoli N, Obermayer-Pietsch B, Palermo A, Pepe J, Peters E, Pierroz DD, Rizzoli R, Saunders DP, Stanford CM, Sulimani R, Taguchi A, Tanaka S, Watts NB, Zamudio J, Zillikens MC, Ruggiero SL. Antiresorptive Therapy to Reduce Fracture Risk and Effects on Dental Implant Outcomes in Patients With Osteoporosis: A Systematic Review and Osteonecrosis of the Jaw Taskforce Consensus Statement. *Endocr Pract.* 2025 May;31(5):686-698. doi: 10.1016/j.eprac.2025.02.016.
 11. Lin L, Ren Y, Wang X, Yao Q. Effects of Bisphosphonates and Denosumab on Dental Implants: A Systematic Review With Meta-Analysis. *Oral Dis.* 2025 Oct;31(10):2835-2847. doi: 10.1111/odi.15373.
 12. Mirza R, El Rabbany M, Ali DS, Tetradis S, Morrison A, Ruggiero S, Alnajimi R, Khan AA, Guyatt G. Dental Implant Failure and Medication-Related Osteonecrosis of the Jaw Related to Dental Implants in Patients Taking Antiresorptive Therapy for Osteoporosis: A Systematic Review and Meta-Analysis. *Endocr Pract.* 2025 Sep;31(9):1189-1196. doi: 10.1016/j.eprac.2025.06.003.
 13. Fernández Ayora A, Herion F, Rompen E, Reginster JY, Magremanne M, Lambert F. Dramatic osteonecrosis of the jaw associated with oral bisphosphonates, periodontitis, and dental implant removal. *J Clin Periodontol.* 2015 Feb;42(2):190-5. doi: 10.1111/jcpe.12322.