



Major maxillary sinus augmentation techniques for dental implant: a systematic review

Gabriela Corrêa Neves Gabioli Coutinho^{1,2*}, Adrieli Chiuchi Scatena^{1,2},
Damiana dos Santos Altero^{1,2}, Fabio Alarcon Idalgo^{1,2}, Alexandre Gomes Nunes^{1,2},
Alvaro José Cicareli^{1,2}

¹ UNORTE - University Center of Northern São Paulo, Dentistry Department, São José do Rio Preto, São Paulo, Brazil.

² UNIPOS - Post Graduate and Continuing Education, Dentistry Department, São José do Rio Preto, São Paulo, Brazil.

*Corresponding author: Gabriela Corrêa Neves Gabioli Coutinho.

Unorte/Unipos - University Center of Northern São Paulo, Dentistry Department, and Postgraduate and continuing education, Sao Jose do Rio Preto, Sao Paulo, Brazil.

E-mail: gabriela_gabioli@hotmail.com

DOI: <https://doi.org/10.54448/mdnt24S211>

Received: 01-18-2024; Revised: 05-24-2024; Accepted: 05-29-2024; Published: 05-30-2024; MedNEXT-id: e24S211

Editor: Idiberto José Zotarelli Filho, MSc., Ph.D., Post-Doctoral.

Abstract

Introduction: In around 25% of all maxillary sinuses, there is an accessory bone that is located in a lower portion than the main ostium. When a dental element is lost in the posterior region of the maxilla, there is natural reabsorption of the alveolar process and at the same time, pneumatization of the maxillary sinus occurs. It will increase its volume towards the location where the roots existed and this will often make it difficult or unfeasible to restore implants in that location. Various surgical techniques can be used to reconstruct the atrophic alveolar ridge, techniques alone or associated with autogenous, allogeneic, xenogeneic grafts, and alloplastic biomaterials. **Objective:** It was to develop a systematic review to list the main clinical and surgical approaches to bone elevation techniques for dental implants. **Methods:** The PRISMA Platform systematic review rules were followed. The search was carried out from January to March 2024 in the Scopus, PubMed, Science Direct, Scielo, and Google Scholar databases. The quality of the studies was based on the GRADE instrument and the risk of bias was analyzed according to the Cochrane instrument. **Results and Conclusion:** A total of 119 articles were found, 35 articles were evaluated in full and 23 were included and developed in the present systematic review study. Considering the Cochrane tool for risk of bias, the overall assessment

resulted in 15 studies with a high risk of bias and 21 studies that did not meet GRADE and AMSTAR-2. Most studies did not show homogeneity in their results, with $X^2=71.6\%>50\%$. It was concluded that the placement of the implant with the simultaneous use of PRP or PRF creates a good relationship between the hard tissue and the soft tissue. The Bio-Oss® biomaterial is one of the most used in guided bone regeneration procedures in regenerative dentistry, and its particles become an integral part of the newly formed bone structure and retain their volume in the long term. Furthermore, Bio-Oss® offers a lot of space for the formation of blood vessels (angiogenesis) and the deposit of neofomed bone, helping the growth of osteoblasts. Notable studies have shown results on the combined use of Bio-Oss® and PRF. Also, it is possible to develop a pre-operative planning method, associated with the area of implant dentistry, using digital images. Furthermore, the conventional surgical guide has some advantages such as being cheaper, simpler, and easier to perform, however, it leads to a greater operative risk for the patient. However, the accuracy of the location to be implanted is not the best and there is a greater probability of this guide becoming worn out, due to the contact of the drills with it.

Keywords: Maxillary sinus augmentation. Alveolar atrophic. Alveolar ridge. Biomaterials. Dental implant.

Introduction

In around 25% of all maxillary sinuses, there is an accessory bone that is located in a lower portion than the main ostium, and all the mucus produced and the particles trapped in this mucus are directed through the ciliary beat to the ostium [1]. When a dental element is lost in the posterior region of the maxilla, there is natural reabsorption of the alveolar process and at the same time, pneumatization of the maxillary sinus occurs. It will increase its volume towards the location where the roots existed and this will often make it difficult or unfeasible to restore implants in that location [1,2].

For this reason, the maxillary sinus floor elevation procedure should be performed, or short implants should be performed when possible. When graft procedures are required, our focus is often on the type of biomaterial to be used and in fact, the success and predictability of our results do not depend solely on the biomaterial. It is also necessary to consider the type of defect to be treated, and its morphology [3].

The morphology will have an impact mainly because the defects have different vascularization capacities, different osteogenic cell recruitment capacities, have different natural stabilization capacities of the grafts, therefore, we must consider the characteristics of the biomaterial that we must use, but also, the characteristics of the bed and the bone defect that we intend to treat. Various surgical techniques can be used to reconstruct the atrophic alveolar ridge, techniques alone or associated with autogenous, allogeneic, xenogeneic grafts, and alloplastic biomaterials. The autogenous bone graft is the only one capable of presenting three important biological properties (osteogenesis, osteoinduction, and osteoconduction) guaranteeing a self-regenerative potential [1-3].

The disadvantage of autogenous bone grafting is the need for second surgical access in the donor area, resulting in longer surgical time, morbidity, and a consequent greater resistance of the patient to the proposed treatment. In this context, allogeneic, xenogeneic, and alloplastic bone grafts present themselves as an alternative for the treatment of bone deficiencies in the jaw, as they avoid the need for a second surgical access. However, due to the need for processing to eliminate antigenic components, these grafts are solely osteoconductive with a lower bone formation potential compared to autogenous bone grafts. To increase the bone formation potential of these grafts, combinations have been proposed to obtain better regenerative conditions through volume preservation (osteoconduction) and induction of cell

migration differentiation (osteoinduction) [1].

Moreover, platelet concentrates have been proposed as regenerative materials in tissue regeneration procedures. Among the platelet concentrates proposed in the literature are PRP (platelet-rich plasma) and PRF (fibrin-rich plasma) which act as autogenous platelet aggregates with osteoinductive properties. These biomaterials, due to low morbidity and possible regenerative potential, have been indicated for use in combination with other biomaterials or even alone. PRF is a second-generation concentrate, that is, no anticoagulant is used to acquire it. The patient's blood, after being collected, is subjected to a specific centrifugation force, and thus, the formed elements are separated according to their density. From this, the part corresponding to red blood cells is discarded and the resulting platelet concentrate is used for regenerative purposes. Leukocytes and platelets synthesize and release a variety of cytokines and growth factors that act in chemotaxis, angiogenesis, differentiation, and cellular inhibition [1,2].

Also, xenografts are bone minerals derived from animals algae and corals. The organic component is removed to eliminate the risk of immunogenic responses or disease transmission. Animal derivatives are the most used in guided bone regeneration, especially deproteinized sterilized bovine medullary bone, which has been extensively researched and shown to have similarities to human medullary bone. Also, deproteinized sterilized bovine medullary bone is an excellent osteoconductor, providing a favorable framework for bone formation. Its slow reabsorption contributes greatly to maintaining graft volume. It has good wettability and a good surface contact angle, favoring contact with the blood clot. Maxillary sinus floor elevations performed exclusively using deproteinized sterilized bovine medullary bone demonstrate good osteoconductive capacity and excellent biological integration, which facilitates new bone formation [3].

The xenograft most used in guided bone regeneration procedures is deproteinized bovine bone mineral, commercially known as Bio-Oss®, it is the most researched product in regenerative dentistry worldwide. It is bone of bovine origin processed to produce natural bone minerals without organic elements. After thermal and chemical treatments, the inorganic phase of bovine bone consists mainly of hydroxyapatite (HA) which retains the porous architecture. The excellent osteoconductive properties of Bio-Oss® lead to predictable and efficient bone regeneration, the Bio-Oss® particles become an

integral part of the newly formed bone structure and retain their volume in the long term [4].

Given this, although the results do not seem to confirm that PRF is better than other biomaterials, it is suggested that its use may result in a decrease in the total healing time, around 104 days, and improve the handling of the graft material. Furthermore, the use of PRF associated with Bio-Oss® appears to illustrate high success rates with minimal costs, potentially reducing the amount of bone graft needed to fill the sinus cavity, reducing procedure costs.

Therefore, the present study developed a systematic review to list the main clinical and surgical approaches to bone elevation techniques for dental implants.

Methods

Study Design

The present study followed the international systematic review model, following the rules of PRISMA (preferred reporting items for systematic reviews and meta-analysis). Available at: <http://www.prisma-statement.org/?AspxAutoDetectCookieSupport=1>. Accessed on: 01/21/2024. The methodological quality standards of AMSTAR-2 (Assessing the methodological quality of systematic reviews) were also followed. Available at: <https://amstar.ca/>. Accessed on: 01/21/2024.

Data Sources and Research Strategy

The literary search process was carried out from January to February 2024 and was developed based on Scopus, PubMed, Web of Science, Lilacs, Ebsco, Scielo, and Google Scholar, covering scientific articles from various to the present. The descriptors (DeCS / MeSH Terms) were used: "Maxillary sinus augmentation. Alveolar atrophic. Alveolar ridge. Biomaterials. Dental implant" and using the Boolean "and" between the MeSH terms and "or" between historical discoveries.

Study Quality and Risk of Bias


Quality was classified as high, moderate, low, or very low in terms of risk of bias, clarity of comparisons, precision, and consistency of analyses. The most evident emphasis was on systematic review articles or meta-analyses of randomized clinical trials, followed by randomized clinical trials. The low quality of evidence was attributed to case reports, editorials, and brief communications, according to the GRADE instrument. The risk of bias was analyzed according to the Cochrane instrument by analyzing the Funnel Plot graph (Sample size versus Effect size), using the Cohen test (d).

Results and Discussion

Summary of Findings

A total of 119 articles were found that were subjected to eligibility analysis, with 23 final studies being selected to compose the results of this systematic review. The studies listed were of medium to high quality (Figure 1), considering the level of scientific evidence of studies such as meta-analysis, consensus, randomized clinical, prospective, and observational. The biases did not compromise the scientific basis of the studies. According to the GRADE instrument, most studies showed homogeneity in their results, with $X^2=71.6\%>50\%$. Considering the Cochrane tool for risk of bias, the overall assessment resulted in 15 studies with a high risk of bias and 21 studies that did not meet GRADE and AMSTAR-2.

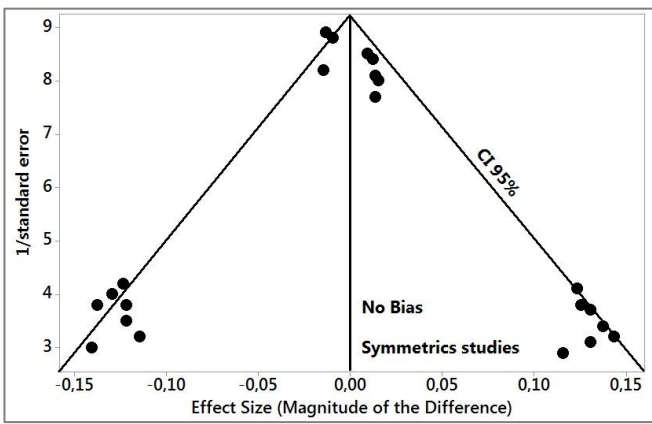
Figure 1. The article selection process by the level of methodological and publication quality.



Source: Own authorship.

Figure 2 presents the results of the risk of bias of the studies using the Funnel Plot, showing the calculation of the Effect Size (Magnitude of the difference) using the Cohen Test (d). Precision (sample size) was determined indirectly by the inverse of the standard error (1/Standard Error). This graph had a symmetrical behavior, not suggesting a significant risk of bias, both between studies with a small sample size (lower precision) that are shown at the bottom of the graph and in studies with a large sample size that are presented at the top.

Figure 2. The symmetric funnel plot suggests no risk of bias among the small sample size studies that are shown at the bottom of the graph. High confidence and high recommendation studies are shown above the graph (n=23 studies).



Source: Own authorship.

Major Clinical Findings

After a complete analysis of the studies, it was found that care in the implant dentistry process is very important, given that the lack of bone in the alveolar crests has been a major problem in the functional aesthetic recovery in patients with dentoalveolar trauma, extractions dental problems, periodontal disease, congenital missing teeth, maxillary and mandibular pathologies, in addition to infections due to emotional and the possibility of deformities due to the lack of protein load [1-3].

In this context, fibrin-rich plasma (PRF) contains leukocytes, platelets, and growth factors, forming a fibrin matrix with a three-dimensional architecture. It is the second generation of platelet concentrate with a high potential for injury repair. It is based on the protection of growth factors from proteolysis that can maintain their activity for a longer period and stimulate bone regeneration more efficiently [5,6].

In this aspect, the development of optimized implant surfaces is the subject of major research to accelerate the osseointegration process, leading to a reduction in waiting time before loading, in addition to making immediate implant loading safer. It was documented for the first time that the combination of biomaterial and PRF significantly improved bone regeneration in the peri-implant zone. The placement of the implant with the simultaneous use of PRP creates a good relationship between the hard tissue and the soft tissue, in addition to the advantage of the psychological relationship with the patient [7,8].

Still in this context, the Bio-Oss® biomaterial is one of the most used in guided bone regeneration procedures in regenerative dentistry. The excellent osteoconductive properties of Bio-Oss® lead to predictable and efficient bone regeneration, BioOss® particles become an integral part of the newly formed bone structure and retain their volume in the long term [1,4]. Furthermore, Bio-Oss® offers a lot of space for the formation of blood vessels (angiogenesis) and the

deposit of neoformed bone [4], helping the growth of osteoblasts.

Based on this, notable studies have shown results on the combined use of Bio-Oss® and PRF. One study clinically and histologically investigated the potential of PRF as a grafting material in pre-implant reconstructive surgeries for severe maxillary atrophy following sinus lift procedures at 106-120-180 days, to determine whether the use of PRF is capable of accelerating the bone regeneration process to promote implant stability. The control group used only Bio-Oss®. As a result, the use of PRF optimized bone formation [1,4,9].

Another study compared the use of Bio-Oss® with PRF and Bio-Oss® with Tisseel® to improve bone regeneration. After elevating the sinus membrane in both maxillary sinus cavities, an implant was placed in the sinus cavity. The PRF/Bio-Oss® composite was grafted and the Tisseel® / Bio-Oss® composite was grafted into the other sinus cavity. After 6 months, the average osseointegration rate was $43.5 \pm 12.4\%$ and the rate of new bone formation was $41.8 \pm 5.9\%$ in PRF/Bio-Oss® composite sites. In the Tisseel® / Bio-Oss® composite sites they were $30.7 \pm 7.9\%$ and $31.3 \pm 6.4\%$. The findings of this study suggested that PRF together with Bio-Oss® particles, bone formation at graft sites is significantly greater than when Tisseel® is used [9].

Thus, the optimized processes of implant dentistry and biomaterials allow the installation of implants in areas of low bone thickness, width, and height, performing simpler surgeries with a higher success rate and patient comfort [10]. The lack of bone in the alveolar crests has been a major problem in functional aesthetic recovery in patients who have suffered dentoalveolar trauma, traumatic tooth extractions, congenital tooth absence, and maxillary and mandibular pathologies [11]. In this sense, bioactivation of the dental implant surface with PRF has been described and discussed by the scientific community as a surface treatment to stimulate and accelerate the osseointegration process, as well as to achieve greater implant stability [12].

In this scenario, guided surgery (GS) in dentistry and advances in technology have contributed to the improvement of models, as only the direct molding technique existed to obtain patient models, with implant positioning that is not very favorable in aesthetic terms [13-16]. The information acquired in 3D reconstructions makes it possible to determine the quantity and quality of available bone and also allows the simulation of implant installation in a virtual environment [17-20].

Furthermore, the use of computed tomography (CT) and developments in guided planning programs are guiding oral surgery precisely toward a specific target.

Thus, virtual dental implant planning allows for a prosthetic approach, resulting in the best possible prosthesis design, better aesthetics, and optimized occlusion and loading [20]. This approach also changed the surgical paradigm of using large flaps to obtain an adequate view of the surgical area, as flapless implant surgery, with or without immediate loading, became more predictable. In this sense, GS refers to the use of a tissue-supported surgical model. This reproduces the virtual position of the implant directly from the computed tomographic data and this information can be converted into guide models to be used during surgery [15-17].

Also, guided dynamic surgery reproduces the virtual position of the implant directly from computed tomographic data and uses motion-tracking technology to guide implant osteotomy preparation [14]. In this way, it became possible to plan the optimal implant position virtually the ideal implant position, taking into consideration the adjacent vital anatomical structures and future prosthetic requirements [21,22].

Thus, the development of programs and the creation of models allowed the tactile perception of the anatomy of the region and the pathology under study, enabling other advantages such as communication between the surgical team, help in communicating with patients, simulation and more detailed surgical planning, processing of personalized implants, reduced surgery time, reduced possible complications during the surgical procedure. In this sense, the imaging exam most used in dentistry capable of providing biomodels is CT, which allows a three-dimensional assessment of the individual anatomy of patients [20-22].

One study evaluated the linear and angular deviations of implants installed using the GS and CT technique. Eighteen patients participated. Ten patients had a completely edentulous maxilla and eight had a completely edentulous mandible. Patients received a total of 115 implants, of which 81 implants were installed in the maxilla and 34 were installed in the mandible. There were no differences in the linear and angular deviations of the implants installed in the maxilla and mandible. Compared to the coronal region, there was a tendency for greater linear deviations in the apical regions of the implants and a greater tendency for deviations in the posterior regions than in the anterior regions of both arches. Therefore, GS by CT promoted the installation of implants with high precision and allowed the installation of straight abutments in all cases evaluated. The linear deviations were not different in different regions of the month and different portions of the implants [19].

Another study looked at the improvement in jaw function, facial aesthetics, and quality of life after

reconstruction of complex jaw defects using the patient-specific three-dimensional titanium implant, with a total of seven patients. There was significant improvement in aesthetics, function, and quality of life. The concept of using customized implants with the help of 3D virtual treatment planning, stereolithographic models, and computer-aided design greatly improves mandibular restoration and helps to achieve good facial profile, aesthetics, and dental rehabilitation by preventing serious complications related to autologous grafts [22].

In this sense, GS is considered accurate and reliable compared to free implant surgery. Implants can be planned based on information from the radiographic guide according to a restored treatment plan. Thus, one study described the use of a digitally designed prosthetic shell to improve the planning accuracy of the weld-guided approach for immediate abutment-supported restorations. As a result, importing the virtual shell into the planning program provided an effective protocol for using definitive prosthetic space information to plan the shape and position of the structure predictably, increasing the accuracy of guided planning and reducing the time required to realign the prosthetic shell [14,15].

A randomized study compared the guided planning accuracy of new model-based computer-assisted implant placement techniques utilizing CAD/CAM stereolithographic surgical models with or without metal sleeves. Forty-one implants were placed using surgical templates with metal sleeves, while 49 implants were placed using a surgical template without metal sleeves. Of these, 16 implants were placed through open sleeves and 33 through closed sleeves. Surgical models without metal sleeves were more accurate in the vertical plane and angle compared to the conventional model. Open sleeves should be used with caution in the molar region only if there is limited space between the squares [21].

Finally, a study evaluated the effects of preoperative guided planning and mandibular reconstruction guided by dental implant rehabilitation on dental prosthesis rehabilitation after jaw reconstruction. Implant surgery was performed 6 months after reconstruction surgery. A total of 101 implants (16 patients) were inserted, and the implant success rate was 98.02%. Guided preoperative planning and dental implant-guided jaw reconstruction through preoperative designs can provide a good opportunity to achieve high implant success rates and dental rehabilitation. This method can also benefit prosthetic restorations supported by fixed implants. Furthermore, the use of navigation after guided planning does not affect the type of prosthetic reconstruction [23].

Conclusion

It was concluded that the placement of the implant with the simultaneous use of PRP or PRF creates a good relationship between the hard tissue and the soft tissue. The Bio-Oss® biomaterial is one of the most used in guided bone regeneration procedures in regenerative dentistry, and its particles become an integral part of the newly formed bone structure and retain their volume in the long term. Furthermore, Bio-Oss® offers a lot of space for the formation of blood vessels (angiogenesis) and the deposit of neoformed bone, helping the growth of osteoblasts. Notable studies have shown results on the combined use of Bio-Oss® and PRF. Also, it is possible to develop a pre-operative planning method, associated with the area of implant dentistry, using digital images. Furthermore, the conventional surgical guide has some advantages such as being cheaper, simpler, and easier to perform, however, it leads to a greater operative risk for the patient. However, the accuracy of the location to be implanted is not the best and there is a greater probability of this guide becoming worn out, due to the contact of the drills with it.

CRedit

Author contributions: **Conceptualization** - Gabriela Corrêa Neves Gabioli Coutinho, Adrieli Chiuchi Scatena; **Data curation** - Gabriela Corrêa Neves Gabioli Coutinho, Adrieli Chiuchi Scatena, Damiana dos Santos Altero; **Formal Analysis** - Fabio Alarcon Idalgo, Alexandre Gomes Nunes, Alvaro José Cicareli; **Investigation** - Gabriela Corrêa Neves Gabioli Coutinho, Adrieli Chiuchi Scatena, Damiana dos Santos Altero; **Methodology** - Gabriela Corrêa Neves Gabioli Coutinho; **Project administration** - Alvaro José Cicareli; **Supervision** - Fabio Alarcon Idalgo; **Writing - original draft** - Gabriela Corrêa Neves Gabioli Coutinho, Adrieli Chiuchi Scatena; **Writing-review & editing** - Gabriela Corrêa Neves Gabioli Coutinho, Alvaro José Cicareli.

Acknowledgment

Not applicable.

Ethical Approval

Not applicable.

Informed Consent

Not applicable.

Funding

Not applicable.

Data Sharing Statement

No additional data are available.

Conflict of Interest

The authors declare no conflict of interest.

Similarity Check

It was applied by Ithenticate®.

Peer Review Process

It was performed.

About The License©

The author(s) 2024. The text of this article is open access and licensed under a Creative Commons Attribution 4.0 International License.

References

1. Li X, Lin SC, Duan SY. The impact of deproteinized bovine bone particle size on histological outcomes in sinus floor elevation: a systematic review and metaanalysis. *Int J Implant Dent.* 2023 Oct 2;9(1):35. doi: 10.1186/s40729-023-00502-1.
2. Cinar IC, Zboun M, Gultekin BA, Saglanmak A, Akay AS. Retrospective analysis of three different xenografts in maxillary sinus augmentation: histologic and three-dimensional radiologic study. *Quintessence Int.* 2023 Sep 19;54(8):640649. doi: 10.3290/j.qi.b4146671.
3. Starch-Jensen T, Bruun NH, Spin-Neto R. Outcomes following osteotomymediated sinus floor elevation with Bio-Oss Collagen or no grafting material: a one-year single-blind randomized controlled trial. *Int J Oral Maxillofac Surg.* 2023 Sep;52(9):988-997. doi: 10.1016/j.ijom.2022.12.009.
4. You JS, Kim SG, Oh JS, Kim JS. Effects of Platelet-Derived Material (PlateletRich Fibrin) on Bone Regeneration. *Implant Dent.* 2019 Mar 8 [doi: 10.1097/ID.0000000000000877].
5. Abdel-Kader, M.A., Abdelazeem, A.F., Ahmed, N.E.B., Khalil, Y.M., Mostafa, M.I. Oral rehabilitation of a case with regional odontodysplasia using a regenerative approach-A case report and a review of literature. *Spec Care Dentist.* 2019, May;39(3):330-339. doi: 10.1111/scd.12378. Epub 2019 Apr 16.
6. Chiapasco M., Casentini P., Zaniboni M. Bone augmentation procedures in implant dentistry. *Int J Oral Maxillofac Implants.* 2009;24 Suppl: 237-59.

7. Choukroun J, Diss A, Simonpieri A, Girard M.O, Schhoeffler C., Dohan S.L., et al. Platelet-rich-fibrin (PRF): a second generation platelet concentrate. Part IV: clinical effects on tissue healing. *Oral Surg. Oral Med. Oral Pathol. Oral Radiol. Endod* 2006; 101 (3): e 56 – 60.
8. Diana, C., Mohanty, S., Chaudhary, Z., Kumari, S., Dabas, J., Bodh, R. Does platelet-rich fibrin have a role in osseointegration of immediate implants? A randomized, single-blind, controlled clinical trial. *Int J Oral Maxillofac Surg.* 2018 Sep;47(9):1178-1188. doi: 10.1016/j.ijom.2018.01.001. Epub 2018 May 7.
9. Canellas JVDS, Drugos L, Ritto FG, Fischer RG, Medeiros PJD. Xenograft materials in maxillary sinus floor elevation surgery: a systematic review with network meta-analyses. *Br J Oral Maxillofac Surg.* 2021 Feb 23:S02664356(21)00075-9. doi: 10.1016/j.bjoms.2021.02.009. Epub ahead of print. PMID: 34120778.
10. Kyak S, Blatt S, Schiegnitz E, Heimes D, Staedt H, Thiem DGE, Sagheb K, AlNawas B, Kämmerer PW. Activation of Human Osteoblasts via Different Bovine Bone Substitute Materials With and Without Injectable Platelet Rich Fibrin in vitro. *Front Bioeng Biotechnol.* 2021 Feb 17;9:599224. doi: 10.3389/fbioe.2021.599224. PMID: 33681155; PMCID: PMC7925396.
11. Shen MH, Huang YL, Li Z, Zhang YD, He YP, Wang L. [Effect of platelet rich fibrin combining with Bio-oss to treat furcation involvement]. *Shanghai Kou Qiang Yi Xue.* 2018 Oct;27(5):508-512. Chinese. PMID: 30680396.
12. Xuan F, Lee CU, Son JS, Jeong SM, Choi BH. A comparative study of the regenerative effect of sinus bone grafting with platelet-rich fibrin-mixed Bio-Oss® and commercial fibrin-mixed Bio-Oss®: an experimental study. *J Craniomaxillofac Surg.* 2014 Jun;42(4):e47-50 [doi: 10.1016/j.jcms.2013.05.029. Epub 2013 Aug 2].
13. Tahmaseb A, Wu V, Wismeijer D, et al. The accuracy of static computer-aided implant surgery: a systematic review and meta-analysis. *Clin Oral Implants Res;* 29(Suppl 16):416–35, 2018.
14. Tahmaseb A, Wismeijer D, Coucke W, et al. Computer technology applications in surgical implant dentistry: a systematic review. *Int J Oral Maxillofac Implants;* 29(Suppl):25–42, 2014.
15. Jung RE, Schneider D, Ganeles J, et al. Computer technology applications in surgical implant dentistry: a systematic review. *Int J Oral Maxillofac Implants;* 24(Suppl):92–109, 2009.
16. D'Haese J, Van De Velde T, Komiyama A, et al. Accuracy and complications using computer-designed stereolithographic surgical guides for oral rehabilitation by means of dental implants: a review of the literature. *Clin Implant Dent Relat Res;*14:321–35, 2012.
17. Oh JH, An X, Jeong SM, et al. Digital workflow for computer-guided implant surgery in edentulous patients: a case report. *J Oral Maxillofac Surg ;*75: 2541–9, 2017.
18. El Kholly K, Janner SFM, Schimmel M, et al. The influence of guided sleeve height, drilling distance, and drilling key length on the accuracy of static computer-assisted implant surgery. *Clin Implant Dent Relat Res;*21(1):101–7, 2019.
19. Zhou W, Liu Z, Song L, et al. Clinical factors affecting the accuracy of guided implant surgery—a systematic review and meta-analysis. *J Evid Based Dent Pract;*18:28–40, 2018.
20. Raico Gallardo YN, Da Silva-Olivio IRT, Mukai E, et al. Accuracy comparison of guided surgery for dental implants according to the tissue of support: a systematic review and meta-analysis. *Clin Oral Implants Res;* 2017;28:602–12.
21. Seo C, Juodzbaly G. Accuracy of guided surgery via stereolithographic mucos-supported surgical guide in implant surgery for edentulous patient: a systematic review. *J Oral Maxillofac Res;* 2018, 9:e1.
22. Cassetta M, Bellardini M. How much does experience in guided implant surgery play a role in accuracy? A randomized controlled pilot study. *Int J Oral Maxillofac Surg;*46:922–30, 2017.
23. Zhu H, Zhang L, Cai Z, Shan X. Dental Implant Rehabilitation After Jaw Reconstruction Assisted by Virtual Surgical Planning. *Int J Oral Maxillofac Implants.* 2019 Feb 19. doi: 10.11607/jomi.7278.