



Major clinical outcomes of minimally traumatic and aesthetic post-tooth extraction: a systematic review

Rebeca Rocha Martim^{1,2*}, Livia Alves Moreira^{1,2}, Giovana Cezar Silva^{1,2},
Andreia Borges Scriboni^{1,2}

¹ UNORTE - University Center of Northern São Paulo, Dentistry Department, São José do Rio Preto, São Paulo, Brazil.

² UNIPOS - Post Graduate and Continuing Education, Dentistry Department, São José do Rio Preto, São Paulo, Brazil.

*Corresponding author: Rebeca Rocha Martim.

Unorte/Unipos - University Center of Northern São Paulo, Dentistry Department, and Postgraduate and continuing education, Sao Jose do Rio Preto, Sao Paulo, Brazil.

E-mail: rebeca.martim@gmail.com

DOI: <https://doi.org/10.54448/mdnt24S210>

Received: 03-08-2024; Revised: 05-17-2024; Accepted: 05-19-2024; Published: 05-22-2024; MedNEXT-id: e24S210

Editor: Idiberto José Zotarelli Filho, MSc., Ph.D., Post-Doctoral.

Abstract

Introduction: After tooth extraction, the alveolar ridge will commonly decrease in volume and change morphologically. These changes can be difficult or even impede the placement of dental implants and prosthetic rehabilitation. Minimizing bone remodeling means optimizing the aesthetics and functional aspects, and mainly, the success of implant treatment. To avoid residual ridge resorption different techniques and bone graft materials have been proposed. **Objective:** A systematic review was carried out to identify the main clinical outcomes of minimally traumatic and aesthetic tooth extraction. **Methods:** The PRISMA Platform systematic review rules were followed. The search was carried out from January to February 2024 in the Scopus, PubMed, Science Direct, Scielo, and Google Scholar databases. The quality of the studies was based on the GRADE instrument and the risk of bias was analyzed according to the Cochrane instrument. **Results and Conclusion:** A total of 189 articles were found, 45 articles were evaluated in full and 36 were included and developed in the present systematic review study. Considering the Cochrane tool for risk of bias, the overall assessment resulted in 35 studies with a high risk of bias and 41 studies that did not meet GRADE and AMSTAR-2. Most studies did not show homogeneity in their results, with $X^2=72.5\%>50\%$. The present study suggests that the

alveolar graft technique may increase the risk of disease transmission, cost, and time of treatment. Several studies have stated that the graft material is not fully incorporated into the newly formed bone, indicating less vital bone tissue. Spontaneous scarring is still the most used feature since, in intact alveoli and small defects, it is a procedure that does not present significant losses that justify the use of edge preservation techniques. In larger defects, techniques after spontaneous healing, such as a block graft, can be used without the drawbacks of alveolar grafting, such as delayed healing and poor bone quality. The use of a buccal subepithelial connective tissue graft for extraction sockets in the anterior maxilla can be considered a predictable approach to preserving the contour of the alveolar ridge.

Keywords: Extraction socket. Alveolar ridge preservation. Tooth extraction. Minimally traumatic. Aesthetic tooth extraction.

Introduction

After tooth extraction, several sequential events arise causing significant qualitative and quantitative changes in the edentulous site. The socket healing process results in dimensional changes of the underlying bone crest as well as the architecture of the overlying soft tissue [1]. The loss of soft tissue contour after tooth extraction may persist after healing, regardless of the

use of alveolar ridge preservation techniques [2].

As aesthetics is the primary concern for most patients, soft tissue grafting is becoming a routine in daily clinical practice to compensate for the decrease in suprarenal tissue dimension that often occurs after tooth loss and implant placement. Such procedures have a role in increasing tissue thickness, reestablishing an adequate width of keratinized tissue, correcting mucogingival deformities, and improving esthetics around teeth and dental implants [3-8].

Also, initially designed to solve cases of total edentulism, according to a specific clinical protocol for fixed dental prosthesis, treatment with osseointegrated dental implants however, became a frequent procedure in replacing a single missing tooth and showed predictable results [1-3]. Tooth extraction is a traumatic procedure that usually results in damage to the surrounding alveolar bone and surrounding soft tissues. Others reported that reabsorption appears to be progressive and irreversible and have observed that the alveolar ridge will generally decrease in volume and morphologically alter. They believe that this occurs due to the quantitative and qualitative changes that the edentulous areas of the alveolar process will suffer after tooth extraction [7,8].

This bone remodeling can generate damages that involve the installation, aesthetics, survival, and function of the implant in the long term. Especially when aesthetic areas are observed, these changes generate obvious consequences for future treatment with implants [4]. Currently, the success of the treatment is not only evaluated by the survival of the implants but also by the aesthetic and functional results. Thus, we should limit the loss of height and width of the alveolar ridge to the minimum, providing a better area for the placement of dental implants [9].

The preservation of the alveolar ridge performed immediately after tooth extraction can bring benefits such as reducing operating costs for both the patient and the dentist and the need for future surgical interventions. Preventing bone remodeling resulting in physiological resorption and the need for future interventions is certainly more effective, although there are many techniques for increasing the ridge [10].

In attempting to neutralize bone remodeling, several approaches have been suggested such as the immediate placement of implants, the use of different graft materials associated or not with the use of occlusive membranes, which would avoid the tendency of soft tissues to invaginate in the alveolus, in addition to without access [11].

The maintenance procedures of the post-extraction alveolar ridge corroborate for placement of the implant

in an esthetic and functionally more favorable position because they are predictable procedures that certainly prevent the depression of the collar. Today, fresh extraction cells represent a challenge for the dental surgeon. Much research has been done on the use of synthetic materials to replace, repair, or augment biological tissues. Therefore, a careful evaluation of the risks and benefits of the use of biomaterials should be carried out, with full knowledge by the dental surgeon regarding the characteristics, properties, and concentration of the materials [1,12].

Therefore, the present study carried out a systematic review to point out the main clinical outcomes of minimally traumatic and aesthetic tooth extraction.

Methods

Study Design

The present study followed the international systematic review model, following the rules of PRISMA (preferred reporting items for systematic reviews and meta-analysis). Available at: <http://www.prisma-statement.org/?AspxAutoDetectCookieSupport=1>. Accessed on: 03/26/2024. The methodological quality standards of AMSTAR-2 (Assessing the methodological quality of systematic reviews) were also followed. Available at: <https://amstar.ca/>. Accessed on: 03/26/2024.

Data Sources and Research Strategy

The literary search process was carried out from January to February 2024 and was developed based on Scopus, PubMed, Web of Science, Lilacs, Ebsco, Scielo, and Google Scholar, covering scientific articles from various to the present. The descriptors (MeSH Terms) were used: "*Extraction socket. Alveolar ridge preservation. Tooth extraction. Minimally traumatic. Aesthetic tooth extraction*" and using the Boolean "and" between the MeSH terms and "or" between historical discoveries.

Study Quality and Risk of Bias

Quality was classified as high, moderate, low, or very low in terms of risk of bias, clarity of comparisons, precision, and consistency of analyses. The most evident emphasis was on systematic review articles or meta-analyses of randomized clinical trials, followed by randomized clinical trials. The low quality of evidence was attributed to case reports, editorials, and brief communications, according to the GRADE instrument. The risk of bias was analyzed according to the Cochrane instrument by analyzing the Funnel Plot graph (Sample size versus Effect size), using the Cohen test (d).

Results and Discussion

Summary of Findings

A total of 189 articles were found that were subjected to eligibility analysis, with 36 final studies being selected to compose the results of this systematic review. The studies listed were of medium to high quality (Figure 1), considering the level of scientific evidence of studies such as meta-analysis, consensus, randomized clinical, prospective, and observational. The biases did not compromise the scientific basis of the studies. According to the GRADE instrument, most studies showed homogeneity in their results, with $\chi^2=72.5\%>50\%$. Considering the Cochrane tool for risk of bias, the overall assessment resulted in 35 studies with a high risk of bias and 41 studies that did not meet GRADE and AMSTAR-2.

Figure 1. The article selection process by the level of methodological and publication quality.

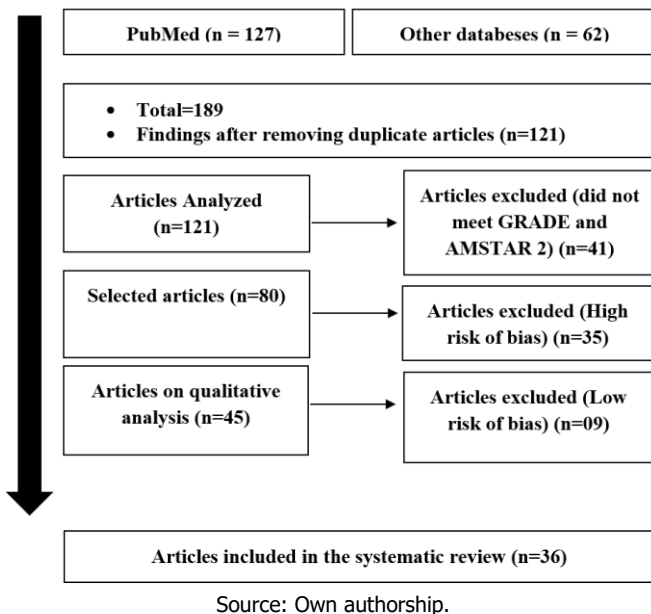
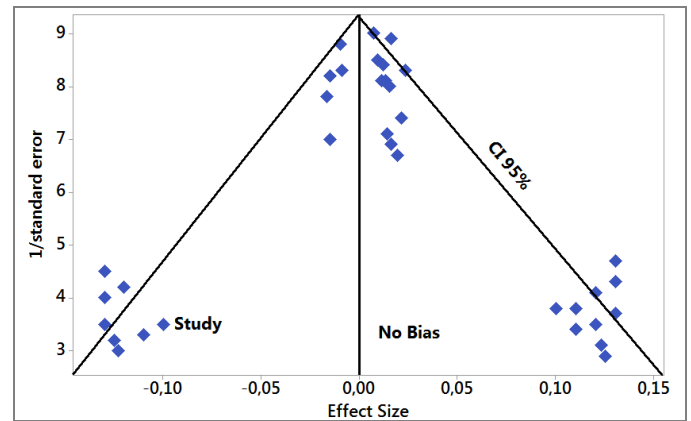


Figure 2 presents the results of the risk of bias of the studies using the Funnel Plot, showing the calculation of the Effect Size (Magnitude of the difference) using the Cohen Test (d). Precision (sample size) was determined indirectly by the inverse of the standard error (1/Standard Error). This graph had a symmetrical behavior, not suggesting a significant risk of bias, both between studies with a small sample size (lower precision) that are shown at the bottom of the graph and in studies with a large sample size that are presented at the top.

Figure 2. The symmetric funnel plot suggests no risk of bias among the small sample size studies that are shown at the bottom of the graph. High confidence and high recommendation studies are shown above the graph (n=36 studies).



Source: Own authorship.

Major Findings

According to literary findings, the morphology and dimensions of the post-extraction alveolar ridge are important for the surgical and restorative phases of implant treatment. Adequate formation of new bone and preservation of alveolar ridge dimensions after extraction will facilitate placement of the implant in a restorative position, while preservation of soft tissue contour and volume is essential for an aesthetic, tissue-implant-supported restoration. healthy peri-implants. Alveolar ridge preservation (ARP) refers to any procedure that aims to limit dimensional changes in the alveolar ridge after extraction, facilitating implant placement without additional extensive bone and soft tissue augmentation procedures, promoting new bone formation in the healing socket, and promoting the healing of soft tissues at the socket entrance and preserve the contour of the alveolar ridge [13].

Based on this, a study evaluated the safety and effectiveness of using autogenous dentin biomaterial in preserving the alveolar ridge. Patients with non-restorable upper anterior teeth bordered by sound natural teeth were included in this study. A total of 32 eligible patients were included in this study (n=16 in each group). Both groups had significantly greater facial soft tissue thickness after four months than the baseline value. However, the study group showed smaller, statistically significant dimensional changes than the control group, according to the standardized images. Furthermore, biopsies confirmed excellent remodeling of the autogenous dentin biomaterial in the study group. In comparison, only thin new bone alveoli filled with trabeculae were in the control group [14].

A randomized clinical trial was to evaluate alveolar ridge contour after soft tissue augmentation using buccal subepithelial connective tissue graft (SCTG) for fresh extraction sockets in patients with thin buccal bone, versus minimally traumatic extraction followed by spontaneous healing only. A total of 40 non-

restorable upper teeth in the aesthetic zone were randomly divided into two groups: minimally traumatic extraction with SCTG (test) and minimally traumatic extraction followed by spontaneous healing (control). The results evaluated included linear volumetric change in the contour of oral soft tissues, vertical tissue loss, gingival thickness (GT), and interdental papilla height (IDP) after 6 months. The SCTG group showed significant improvement in all outcomes after 6 months. The SCTG group showed a statistically significant gain in the volumetric change of oral soft tissues compared to the control group. The SCTG group showed a statistically significant increase in GT and IDP height after 6 months compared to the control group [15].

The main purpose of alveolar grafting is to preserve the alveolar ridge anatomy and optimize implant placement in an ideal three-dimensional position required for functional and aesthetic rehabilitation [1,2]. Within the synthetic materials used to fill the alveolus, the deproteinized bovine bone (spongy, cortical, or the mixture of both) associated or not to the use of guided tissue regeneration technique seems to be the most common [3-11].

It has been stated that in intact wall alveoli we can use osteoconductive materials and the use of membranes may not be necessary. Guided tissue regeneration techniques, with osteoinductive materials associated or not with the use of regenerative membranes, are used in alveoli with compromised walls or the absence of any wall [16-18].

Significant three-dimensional bone loss was reported in addition to reducing the quality and quantity of keratinized gingiva in alveoli without adequate treatment, emphasizing the importance of using appropriate materials and demonstrating better results with the use of Bio-Oss® compared to NanoBone. Preservation of the collar using deproteinized mineral bovine bone (Bio-Oss®) and nanocrystalline hydroxyapatite (NanoBone), together with a collagen membrane, reduced alveolar ridge changes after tooth extraction and allowed for a more favorable implant positioning. There was no superiority between histological and histomorphometric materials [19].

The deproteinized bovine bone particles inserted into the bone defects can not be fully resorbed and remain around the recipient's bone as inert foreign bodies. The study also cites other authors, who report osteoclastic activity after months of healing, suggesting that over time these particles will remodel and form new bone. This remodeling would occur only 10% per year [20-24]. A considerable limitation in horizontal and vertical resorption was observed using the preservation of the alveolus with bovine mineral bone and porcine collagen membrane when compared with spontaneous

healing, also histologically observing the formation of new bone with large mineralized portion due to the xenograft material [25-29].

The alveolus was filled with a matrix composed of mineralized and demineralized allografts together with an absorbable collagen membrane and histologically observed bone formation in three healing periods. The authors reported that osseointegration occurred independently of the moment of grafting and that the presence, especially at early times, of intense osteoblastic activities, suggesting a permanently active bone regeneration, may have contributed to implant survival [30,31].

In immediate implants, defects of about 1.5 mm between bone walls and implants have shown good spontaneous healing, but to avoid loss of vestibular bone volume, these defects should preferably be filled with biomaterial associated with membranes [32-34]. Although immediate unit implants offer an increased risk of failure, aesthetic results and marginal peri-implant radiographic bone levels are optimized by filling the defect around immediate unit implants using an inorganic bovine bone substitute (Endobone) with resorbable collagen (OsseoGuard) [35,36].

Finally, one study evaluated alveoli with hydroxyapatite, biphasic calcium phosphate, tricalcium phosphate, and alveoli without any type of graft. They observed that bone formation was late in the grafted alveoli with synthetic bone filling and that the healing process was different according to the biodegradation pattern. In addition, they noted that alveoli grafted with tricalcium phosphate had fewer residual particles in all healing periods [11]. With current advances in stem cell technology, in the future, it may be possible to regenerate the teeth or maintain the alveolar bone. Promising results were observed with frameworks grown from mesenchymal stem cells of the bone marrow inserted into fresh alveoli [1-4].

Conclusion

The present study suggests that the alveolar graft technique may increase the risk of disease transmission, cost, and time of treatment. Several studies have stated that the graft material is not fully incorporated into the newly formed bone, indicating less vital bone tissue. Spontaneous scarring is still the most used feature since, in intact alveoli and small defects, it is a procedure that does not present significant losses that justify the use of edge preservation techniques. In larger defects, techniques after spontaneous healing, such as a block graft, can be used without the drawbacks of alveolar grafting, such as delayed healing and poor bone quality. The use of a buccal subepithelial

connective tissue graft for extraction sockets in the anterior maxilla can be considered a predictable approach to preserving the contour of the alveolar ridge.

CRedit

Author contributions: Conceptualization - Rebeca Rocha Martim, Livia Alves Moreira, Giovana Cezar Silva; **Data curation** - Rebeca Rocha Martim, Livia Alves Moreira; **Formal Analysis** - Andreia Borges Scriboni; **Investigation** - Giovana Cezar Silva; **Methodology** - Livia Alves Moreira, Giovana Cezar Silva; **Project administration** - Andreia Borges Scriboni; **Supervision** - Andreia Borges Scriboni; **Writing - original draft** - Rebeca Rocha Martim, Livia Alves Moreira, Giovana Cezar Silva; **Writing-review & editing** - Rebeca Rocha Martim, Andreia Borges Scriboni.

Acknowledgment

Not applicable.

Ethical Approval

Not applicable.

Informed Consent

Not applicable.

Funding

Not applicable.

Data Sharing Statement

No additional data are available.

Conflict of Interest

The authors declare no conflict of interest.

Similarity Check

It was applied by Ithenticate®.

Peer Review Process

It was performed.

About The License©

The author(s) 2024. The text of this article is open access and licensed under a Creative Commons Attribution 4.0 International License.

References

1. Baxi S, Bhatia V, Tripathi AA, Kumar P, Pandey A, Dilip Taide P. Asymmetric Extraction Decision in Orthodontics. *Cureus*. 2023 Jun 8;15(6):e40162. doi: 10.7759/cureus.40162.
2. Udeabor SE, Heselich A, Al-Maawi S, Alqahtani AF, Sader R, Ghanaati S. Current Knowledge on the Healing of the Extraction Socket: A Narrative Review. *Bioengineering (Basel)*. 2023 Sep 29;10(10):1145. doi: 10.3390/bioengineering10101145.
3. Leblebicioglu B, Tatakis DN. Complications following alveolar ridge augmentation procedures. *Periodontol 2000*. 2023 Oct;93(1):221-235. doi: 10.1111/prd.12509.
4. Wittneben JG, Molinero-Mourelle P, Hamilton A, Alnasser M, Obermaier B, Morton D, Gallucci GO, Wismeijer D. Clinical performance of immediately placed and immediately loaded single implants in the esthetic zone: A systematic review and meta-analysis. *Clin Oral Implants Res*. 2023 Sep;34 Suppl 26:266-303. doi: 10.1111/clr.14172.
5. Mardas N, d'aiuto F, Mezzomo L, Arzoumanidi M, Donos N. Radiographic alveolar bone changes following ridge preservation with two different biomaterials. *Clin Oral Implants Res*. 2011; 22, p. 416-423.
6. Bashara H, Wohlfahrt JC, Polyzois I, Lyngstadaa SP, Renvert S, Claffey N. The effect of permanent grafting materials on the preservation of the buccal bone plate after tooth extraction: an experimental study in the dog. *Clin Oral Implants Res*. 2012, 23, p. 911-917.
7. De Angelis N, Felice P, Pellegrino G, Camurati A, Gambino P, Esposito M. Guided bone regeneration with and without a bone substitute at single post-extractive implants: 1-year post-loading results from a pragmatic multicentre randomised controlled trial. *Eur J Oral Implantol*. 2011, 4(4), p. 313-325.
8. Barcelos M, Novaes JRA, Conz M, Harari N, Vidigal JRG. Diagnosis and Treatment of Extraction Sockets in Preparation for Implant Placement: Report of Three Cases. *Braz Dent J*. 2008, 19(2), p. 159-164.
9. Barboza E, Zenobio E, Shibli J, Granjeiro JM, Carvalho PSP, Sendyk WR. Biomateriais substitutos de osso: de onde viemos, onde estamos, para onde vamos? revista perionews, 2011, 5(4), p. 344-350.
10. Aldredge WA, Nejat R. Delayed implant procedure using deproteinized bovine bone mineral: a report of 109 consecutive cases. *compend contin educ dent*, 2011, v. 32, n. 4, p. 66-71.
11. Gholami GA, Najafi B, Mashhadiabbas F, Goetz W, Najafi S. Clinical, histologic and histomorphometric evaluation of socket

- preservation using a synthetic nanocrystalline hydroxyapatite in comparison with a bovine xenograft: a randomized clinical trial. *clin oral impl res*, 2012, 23, p. 1198-1204.
12. Vignoletti F, Matesanz P, Rodrigo D, Figuero E, Martin C, Sanz M. Surgical protocols for ridge preservation after tooth extraction. a systematic review. *clin oral impl res*, 2012, 23, supl. 5, p. 22-38.
 13. Mardas N, Macbeth N, Donos N, Jung RE, Zuercher AN. Is alveolar ridge preservation an overtreatment? *Periodontol* 2000. 2023 Oct;93(1):289-308. doi: 10.1111/prd.12508.
 14. Hussain AA, Al-Quisi AF, Abdulkareem AA. Efficacy of Autogenous Dentin Biomaterial on Alveolar Ridge Preservation: A Randomized Controlled Clinical Trial. *Biomed Res Int*. 2023 Dec 27;2023:7932432. doi: 10.1155/2023/7932432.
 15. Gamal N, Shemais N, Al-Nawawy M, Ghallab NA. Post-extraction volumetric analysis of alveolar ridge contour using subepithelial connective tissue graft in esthetic zone: a randomized controlled clinical trial. *Clin Oral Investig*. 2023 Nov;27(11):6503-6512. doi: 10.1007/s00784-023-05255-0.
 16. Vignoletti F, Discepoli N, Muller A, De Sanctis M, Munoz F, Sanz M. Bone modelling at fresh extraction sockets: immediate implant placement versus spontaneous healing. an experimental study in the beagle dog. *j clin periodontol*, 2012, 39, p. 91-97.
 17. Hammerle CHF, Araujo MG, Simion M. On behalf of the osteology consensus group 2011. evidence-based knowledge on the biology and treatment of extraction sockets. *clin oral impl res*, 2012, 23 (suppl. 5), p. 80-82.
 18. Da Rosa JCM, da rosa DM, Zardo CM, Rosa AC, Canullo L. Restauração dentoalveolar imediata pós-exodontia com implante plataforma switching e enxertia. *revista implantenews*, 2009, v. 6, n. 5, p. 551-558.
 19. Spinato S, Agnini A, Chiesi M, Agnini AM, Wang HL. Comparison between graft and no-graft in an immediate placed and immediate nonfunctional loaded implant. *implant dentistry*, 2012, v. 21, n. 2, p. 97-103.
 20. Levin B, Tawil P. Posterior tooth replacement with dental implants in sites augmented with rhbmp-2 at time of extraction - a case series. *compend contin educ dent*, 2012, v. 33, n. 2, p. 104-112.
 21. Penarrocha-oltra D, Demarchi C, Maestre-Ferrin L, Penarrocha-Diago M, Penarrocha-Diago M. Comparison of immediate and delayed implants in the maxillary molar region: a retrospective study of 123 implants. *j oral maxillofac implants*. 2012, v. 27, n. 3, p. 604-610.
 22. Cardaropoli D, Tamagnone L, Roffredo A, Gaveglio L, Cardaropoli G. Socket preservation using bovine bone mineral and collagen membrane: a randomized controlled clinical trial with histologic analysis. *int j periodontics restorative dent*, 2012, v. 32, n. 4, p. 420-430.
 23. Scheyer ET, Schupbach P, Mcguire MK. A histologic and clinical evaluation of ridge preservation following grafting with demineralized bone matrix, cancellous bone chips, and resorbable extracellular matrix membrane. *J periodontics restorative dent*, 2012, v. 32, n. 5, p. 542-552.
 24. Al-hezaimi K, Rudek I, Al-Hamdan KS, Javed F, Nooh N, Wang HL. Efficacy of using a dual layer of membrane (dptfe placed over collagen) for ridge preservation in fresh extraction sites: a micro-computed tomographic study in dogs. *clin oral imp res*, 2012, p. 1-6.
 25. Margonar R, Queiroz T, Luvizuto ER, Marcantonio E, Lia RCC, Holzhausen M, Marcantonio JRE. Bioactive glass for alveolar ridge augmentation. *j craniofacial surg*, 2012, v. 23, n. 3, p. 220-222.
 26. Agarwal G, Thomas R, Mehta D. Postextraction maintenance of the alveolar ridge: rationale and review. *compend contin educ dent*, 2012, v. 33, n. 5, p. 320-326.
 27. Barone A, Orlando B, Cingano L, Marconcini S, Derchi G, Covani U. A randomized clinical trial to evaluate and compare implants placed in augmented versus non-augmented extraction sockets: 3-year results, *j periodontol*, 2012, v. 83, n.7, p. 836-846.
 28. Suaid F, Grisi MFM, Souza SLS, Palioto DB, Taba JRM, Novaes JR AB. Buccal bone remodeling after tooth extraction using the flapless approach with and without synthetic bone grafting. A histomorphometric study in dogs. *Clin Oral Impl res*, 2013, 24, p. 407-413.
 29. Hong JY, Lee JS, Pang EK, Jung UW, Choi SH, Kim CK. Impact of different synthetic bone fillers on healing of extraction sockets: an experimental study in dogs. *clin oral impl res*, 2012, 00, p. 1-8.
 30. Pagni G, Pellegrini G, William V, Giannobile WV, Rasperini G. Postextraction alveolar ridge preservation: biological basis and treatments. *int j dent*, 2012.
 31. Dalapicula SS, Vidigal JRGM, Conz MB, Cardoso ES. Características físico-químicas dos

- biomateriais utilizados em enxertias ósseas. Uma revisão crítica. *implantnews*, 2006, v. 3, n. 5, p. 487-491.
32. Irinakis T. Rationale for socket preservation after extraction of a single-rooted tooth when planning for future implant placement. *J can dent assoc*, 2006, vol. 72, n. 10, p. 917-922.
 33. Shakibaie B. Comparison of the effectiveness of two different bone substitute materials for socket preservation after tooth extraction: a controlled clinical study. *int j periodontics restorative dent*, 2013, v. 33, n. 2, p. 222-228.
 34. Oliveira RB, Silveira RL, Machado RA. Uso do enxerto desmineralizado homogêneo em alvéolo pós-extração: relato de casos. *Rev cir traumatol buco-maxilo-fac*, 2005, v.5, n.4, p. 31 - 36.
 35. Dantas TS, Lelis ER, Navesb LZ, Fernandes-Neto AJ, Magalhaes D. Materiais de enxerto ósseo e suas aplicações na odontologia. *unopar cient ciênc biol saúde*, 2011, 13(2), p. 131-135.
 36. Peck MT, Marnewick J, Stephen L. Alveolar ridge preservation using leukocyte and platelet-rich fibrin: a report of a case. *case reports in dentistry*, 2011,p. 1-5.