



# Main clinical and surgical outcomes of crossbite treatment: a concise systematic review

Guilherme Nonato Cândido Da Silva<sup>1,2\*</sup>, Victoria Camargo Freitas<sup>1,2</sup>, Douglas Fernando Quarezemin<sup>1,2</sup>, Carlos Alberto Costa Neves Buchala<sup>1,2</sup>

<sup>1</sup> UNORTE - University Center of Northern São Paulo, Dentistry department, São José do Rio Preto, São Paulo, Brazil.

<sup>2</sup> UNIPOS - Post graduate and continuing education, Dentistry department, São José do Rio Preto, São Paulo, Brazil.

\*Corresponding author: Guilherme Nonato Cândido Da Silva.  
Unorte/Unipos – Graduate and Postgraduate education,  
Dentistry department, São José do Rio Preto, São Paulo, Brazil.  
E-mail: guilhermenonato251@gmail.

DOI: <https://doi.org/10.54448/mdnt23401>

Received: 07-04-2023; Revised: 09-29-2023; Accepted: 10-04-2023; Published: 10-09-2023; MedNEXT-id: e23401

## Abstract

**Introduction:** In the crossbite scenario, the prevalence of malocclusion is 56%, with 10% of crossbites in the primary dentition, 11% in the mixed dentition, and 5% in the permanent dentition. The etiology is multifactorial and early diagnosis of crossbite is essential to reduce the risk of dental, alveolar, and skeletal malocclusions. In this sense, malocclusions are a disorder that is increasingly present in the population.

**Objective:** It was to carry out a concise systematic review of the main considerations of crossbite and malocclusions.

**Methods:** The PRISMA Platform systematic review rules were followed. The search was carried out from June to September 2023 in the Scopus, PubMed, Science Direct, Scielo, and Google Scholar databases. The quality of the studies was based on the GRADE instrument and the risk of bias was analyzed according to the Cochrane instrument.

**Results and Conclusion:** A total 117 articles were found, and 22 articles were evaluated in full and 13 were included and developed in the present systematic review study. Considering the Cochrane tool for risk of bias, the overall assessment resulted in 7 studies with a high risk of bias and 43 studies that did not meet GRADE. Early bite correction will provide benefits, restoring the normal redirection of the eruption of permanent teeth, providing correction of asymmetries in condylar positioning, and favoring ideal occlusion. Furthermore, early expansion with a removable expansion plate is a successful method for correcting crossbites and increasing intermolar width in the early phase of mixed dentition. Results remain stable until comprehensive treatment of the permanent dentition begins. Rapid maxillary expansion is a resource of great value to the orthodontist that can be used to treat maxillary transverse deficiencies.

**Keywords:** Crossbite. Malocclusion. Early expansion. Rapid expansion.

## Introduction

In the crossbite scenario, the prevalence of malocclusion is 56%, with 10% of crossbites in the primary dentition, 11% in the mixed dentition, and 5% in the permanent dentition [1,2]. The etiology is multifactorial and may be related to heredity, oral breathing, sucking habits, and factors of occlusal kinetic origin (for example, interference caused by deciduous canines [3,4].

In this context, early diagnosis of crossbite is essential to reduce the risk of dental, alveolar, and skeletal malocclusions, with aesthetic problems and consequent psychosocial impact [1]. The age at which the therapy is performed has psychological effects on the patient and the occurrence of crossbite in the primary dentition promotes changes in craniofacial growth with deleterious consequences proportional to the child's chronological age [2,3].

Thus, malocclusions are a disorder that is increasingly present in the population. The morphology of dental arches is of great importance for adequate chewing, phonetic, and aesthetic action, as well as for swallowing, breathing, and facial harmony. The imbalance of the stomatognathic system is characterized by a disharmony between the dental, skeletal, and muscular structures [5].

Maxillary atresia is a dentofacial deformity of multifactorial origin, characterized by the narrowing of the upper arch in the transverse direction, causing a divergence to the mandible. This atresia is often associated with respiratory and phonetic problems, generating a unilateral or bilateral posterior crossbite, in

addition to dental crowding and high palate. After the diagnosis of atresia, the therapeutic goal is to achieve a normal occlusion, in which the maxilla and mandible maintain a harmonious relationship with each other [5,6].

As a corollary, functional crossbite must receive early treatment, because, on the side where there is the crossbite, the condyle is displaced upwards and backward, or commonly positioned in the glenoid cavity [7]. On the opposite side, the condyle is displaced downwards and forward, leaving the bite with a tendency towards class II on the crossed side and class III. If this transverse deficiency is not treated prematurely, the patient, at the end of the growth phase, will experience mandibular asymmetry due to the remodeling of the TMJ structures [8].

The rapid expansion of the maxilla initially described by Angell in 1860 is one of the means for treating posterior crossbites. This technique is characterized by the opening of the median palatal suture and the disorganization of the other sutures of the craniofacial complex, generating changes at the dental and skeletal levels. To perform this technique, some types of devices are used, such as the Haas circuit-breaker device, the Hyrax circuit-breaker device, and the McNamara circuit-breaker device [9].

Therefore, the present study aimed to carry out a concise systematic review of the main considerations of crossbite and malocclusions.

## Methods

### Study Design

The systematic review rules of the PRISMA Platform Available at: [www.prisma-statement.org/](http://www.prisma-statement.org/) were followed. Accessed on: 08/22/2023.

### Data Sources and Research Strategy

The search strategies for this systematic review were based on the keywords (MeSH Terms): "*Crossbite. Malocclusion. Early expansion. Rapid expansion*". The search was carried out from June to September 2023 in the Web of Science, Scopus, PubMed, Science Direct, Scielo, and Google Scholar databases. Furthermore, a combination of keywords with the Booleans "OR", "AND" and the "NOT" operator was used to target scientific articles of interest.

### Quality of Studies, Eligibility of Articles, and Risk of Bias

Following GRADE recommendations, the quality of scientific evidence in the studies covered was classified as high, moderate, low, or very low, according to the risk of evidence bias, sample size, clarity of

comparisons, precision, and consistency of effects. of the analyses. High-quality evidence was assigned using four criteria: 1) Randomized or prospective controlled clinical trials; 2) Retrospective clinical trials or case series; 3) Sample size greater than 15 participants; 4) Studies with statistically well-designed results; 5) Studies published in indexed journals and with a significant impact factor; 6) descriptive, interpretative, theoretical (credibility of methods) and pragmatic validity.

The Cochrane Instrument was adopted to assess the risk of bias of the studies chosen using the Cohen Test to calculate the effect size – the magnitude of the difference in results between the studies covered in this study (Effect Size) versus the Inverse of the Standard Error (precision or sample size) to determine the Risk of Bias of the studies using the Funnel Plot graph.

## Results and Discussion

### Summary of Findings

A total of 117 articles were found. Initially, duplication of articles was excluded. After this process, the abstracts were evaluated and a new exclusion was carried out, removing articles that did not include the topic of this article, resulting in 37 articles. A total of 22 articles were evaluated in full and 13 were included and developed in the present systematic review study (Figure 1). Considering the Cochrane tool for risk of bias, the overall assessment resulted in 7 studies with a high risk of bias and 43 studies that did not meet GRADE.

Figure 1. Flowchart showing the article selection process.

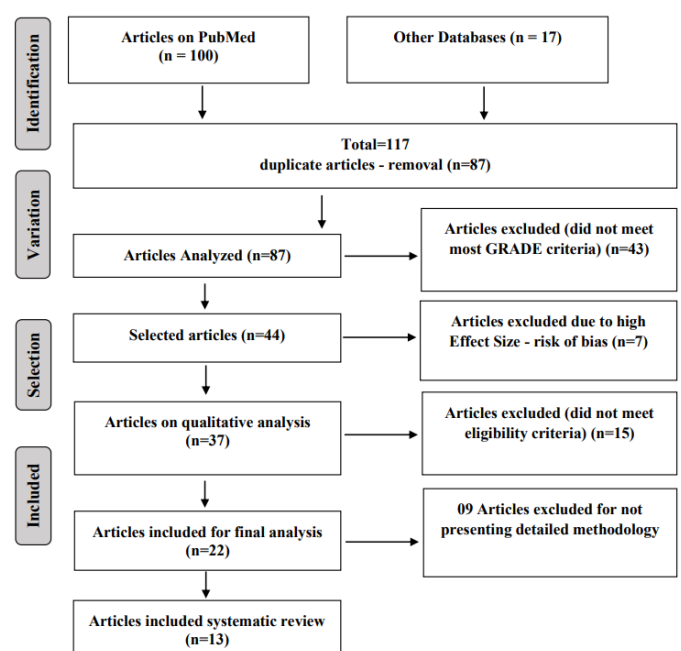
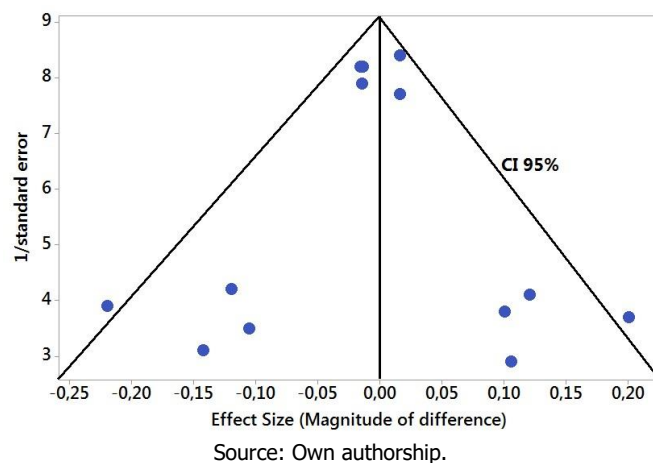


Figure 2 presents the results of the risk of bias of the studies using the Funnel Plot, showing the calculation of the Effect Size (Magnitude of the difference) using the Cohen Test (d). The sample size was determined indirectly by the inverse of the standard error (1/Standard Error). This graph presented symmetrical behavior, not suggesting a significant risk of bias, both between studies with a small sample size (lower precision) that are shown at the base of the graph and in studies with a large sample size that are presented in the upper region.

Figure 2. The symmetric funnel plot suggests no risk of bias among the small sample size studies that are shown at the bottom of the plot. High confidence and high recommendation studies are shown above the graph (NTotal = 13 clinical studies evaluated in full in the systematic review).



### Major Findings - Crossbite

Following the objective of this review work, it was found that a retrospective cohort study evaluated the long-term effects of interceptive orthodontic treatment with a removable expander plate, based on transverse, sagittal, and vertical parameters. 90 patients who required interceptive treatment due to crossbite or space deficiency were included. Records consisting of clinical photos, radiographs, and digital models were collected for evaluation at two moments: the beginning of interceptive treatment (T0) and the beginning of comprehensive treatment (T1). After expansion with removable appliances, a significant increase in intermolar width was achieved and could be maintained during the observation period ( $p < 0.001$ ). However, no significant changes were observed to overjet, overbite, or sagittal occlusion of the molars. Crossbite correction was successful in 86.9% of patients with unilateral crossbite and 75.0% of patients with bilateral crossbite ( $p < 0.001$ ) [10].

In this regard, Angell, in 1860, reported the first

case of rapid maxillary disjunction, verifying the opening of the median palatal suture through clinical evidence such as the widening of the maxillary bone base and the appearance of diastema between the upper central incisors. Due to a lack of studies Angell was discredited, however, almost a century later other researchers returned to exploring the topic [2,3,11].

Maxillary expansion was considered a high-risk procedure by renowned authors such as Angle and Case in the United States. In Europe, the procedure was successfully developed mainly by Korkhaus, which aroused the interest of other researchers, such as Brodie and Haas. Haas began to develop studies in pigs and then in patients that resulted in the development of the device that bore his name – the Haas circuit breaker –, widely used to this day [1,12].

After analyzing the results, Haas found that the small pressure that appeared after activating the screw quickly disappeared; in some cases, it was possible to observe injuries to the soft tissue of the palate below the acrylic portion; changes occurred in the dimensions of the nasal cavity, intermolar and inter incisor distances; there was an increase in the lower intermolar distance; in the vertical direction, the opening of the median palatal suture occurred in a triangular shape with the apex facing the nasal cavity; diastema between the upper central incisors; in the analysis of normal lateral cephalograms, point A moved forward in all cases and downwards in only five cases, causing a clockwise rotation of the mandible [3,12,13].

Subsequently, the use of the Haas circuit breaker became a method increasingly used by orthodontists in the 1960s as an aid in the treatment of cases with maxillary atresia. The device is tooth-much supported and attempts to divide the activation force between the teeth and the palate, concluding that it has been the most beneficial in the treatment of class III and pseudoclass III malocclusions, cases of severe maxillary atresia and patients with nasal insufficiency, enabling that mouth breathers become nasal breathers [12].

In addition to the expected increase in the width of the dental arch, the device also generates high palatal expansion, which corresponds to a significant transverse increase in the deep region of the palate. Clinical evidence of separation of the maxillary processes is achieved by the gradual opening of the diastema between the upper central incisors. The recommended activation protocol will depend on the patient's age and may be 1/4 turn in the morning and 1/4 turn in the evening or 2/4 turn in the morning and 2/4 turn at night. The success of the treatment will depend on the retention time, with three months being recommended with the breaker, followed by six months with an acrylic plate removable [13].

Because the Haas circuit breaker is difficult to clean, Biederman proposed the Hyrax circuit breaker, which does not have an acrylic coating on the palate, making cleaning easier. It is formed by a stainless steel wire buccal bar, an expanding vise located in the center of the median palatal suture, and metal extensions welded to the bands of the upper first molars and first permanent premolars. Its activation is similar to the Haas circuit breaker and must remain stabilized for three months for complete sutural ossification [1,2].

The McNamara breaker was developed with concern for the vertical control of the posterior-superior teeth after expansion, as in the Hyrax breaker there is a greater tendency for the upper molars to procline. The device consists of a metal structure made of 1.0mm stainless steel wire, which fits on the palatal surfaces of the posterior teeth. It is welded to the Hyrax-type expansion screw, in addition to having an acrylic occlusal cover, extending from the palate of the posterior teeth, passing through the occlusal surfaces and ending in the region cervical, by vestibular of the aforementioned group of teeth. The breaker device with occlusal covering recommended by McNamara proved to be well-indicated for patients with a vertical growth pattern at an early age, as it allows the control of the vertical displacement of the maxilla and mandible [2,4].

Some variables that may interfere with the success of maxillary disjunction therapy and the amount of orthopedic expansion are the patient's advancing age, with earlier stages presenting greater orthopedic changes; the magnitude of applied force, and the type of expander used. Early bite correction will provide benefits, restoring the normal redirection of the eruption of permanent teeth, providing correction of asymmetries in condylar positioning, and favoring ideal occlusion [1,2,4].

Rapid maxillary expansion is a resource of great value to the orthodontist that can be used to treat maxillary transverse deficiencies, chronic nasal incapacity that exhibits respiratory problems, and problems associated with arch length. The three devices, despite having differences between them, are equally efficient and produce similar results, with the main dental-skeletal changes being the opening of the median palatal suture, causing a transverse increase in the maxilla, nasal cavity, and interdental distances and also in the perimeter. of the dental arch [1,7].

## Conclusion

Early bite correction will provide benefits, restoring the normal redirection of the eruption of permanent teeth, providing correction of asymmetries in condylar positioning, and favoring ideal occlusion. Furthermore,

early expansion with a removable expansion plate is a successful method for correcting crossbites and increasing intermolar width in the early phase of mixed dentition. Results remain stable until comprehensive treatment of the permanent dentition begins. Rapid maxillary expansion is a resource of great value to the orthodontist that can be used to treat maxillary transverse deficiencies.

## Acknowledgement

Not applicable.

## Ethical Approval

Not applicable.

## Informed consent

Not applicable.

## Funding

Not applicable.

## Data sharing statement

No additional data are available.

## Conflict of interest

The authors declare no conflict of interest.

## Similarity check

It was applied by Ithenticate®.

## Peer Review Process

It was applied.

## About the License

© The authors (s) 2023. The text of this article is open access and licensed under a Creative Commons Attribution 4.0 International License.

## References

1. Urzal V, Iunes T, Pinhão-Ferreira A. A new challenge for crossbite treatment. *Front Oral Health*. 2023 Jul 6;4:1235134. doi: 10.3389/froh.2023.1235134.
2. Alsawaf DH, Almaasarani SG, Hajeer MY, Rajeh N. The effectiveness of the early orthodontic correction of functional unilateral posterior crossbite in the mixed dentition period: a systematic review and meta-analysis. *Prog Orthod*. 2022 Feb 14;23(1):5. doi: 10.1186/s40510-022-00398-4.
3. Zhang J, Yang Y, Han X, Lan T, Bi F, Qiao X, Guo W. The application of a new clear removable



- appliance with an occlusal splint in early anterior crossbite. *BMC Oral Health*. 2021 Jan 21;21(1):36. doi: 10.1186/s12903-021-01393-7.
4. Iodice G, Danzi G, Cimino R, Paduano S, Michelotti A. Association between posterior crossbite, skeletal, and muscle asymmetry: a systematic review. *Eur J Orthod*. 2016 Dec;38(6):638-651. doi: 10.1093/ejo/cjw003.
  5. Agostino P, Uggolini A, Signori A, Silvestrini-Biavati A, Harrison JE, Ortho RP. Orthodontic treatment for posterior crossbites. *Cochrane Database Syst Rev*. 2014, 8:CD000979. 10.1002/14651858.CD000979.pub2.
  6. Kutin G, Hawes RR, Rochester NY. Posterior cross-bites in the deciduous and mixed dentitions. *Am J Orthod*. 1969, 56:491–504. 10.1016/00029416(69)90210-3.
  7. Lombardo G, Vena F, Negri P, Pagano S, Barilotti C, Paglia L, et al. Worldwide prevalence of malocclusion in the different stages of dentition: a systematic review and meta-analysis. *Eur J Paediatr Dent*. 2020, 21:115–22. 10.23804/ejpd.2020.21.02.05.
  8. Katz CR, Rosenblatt A, Gondim PP. Nonnutritive sucking habits in Brazilian children: effects on deciduous dentition and relationship with facial morphology. *Am J Orthod Dentofacial Orthop*. 2004, 126:53–7. 10.1016/j.ajodo.2003.06.011.
  9. Melki-Frèrejouand C, Naulin-Ifi C. Endoalveolia/endognathia: how can transverse abnormalities be treated? *Rev Odont Stomat*. 2018, 47:223–40.
  10. Van de Velde AS, De Boodt L, Cadenas de Llano-Pérula M, Laenen A, Willems G. Long-term effects of orthodontic interceptive expansion treatment : A retrospective study. *J Orofac Orthop*. 2023 Apr 28. English. doi: 10.1007/s00056-023-00467-1.
  11. Urzal V, Braga AC, Ferreira AP. Oral habits as risk factors for anterior open bite in the deciduous and mixed dentition - cross-sectional study. *Eur J Paediatr Dent*. 2013, 14:299-302.
  12. Borrie F, Bearn D. Early correction of anterior crossbites: a systematic review. *J Orthod*. 2011, 38:175-84. 10.1179/14653121141443.
  13. Tung AW, Kiyak HA. Psychological influences on the timing of orthodontic treatment. *Am J Orthod Dentofacial Orthop*. (1998) 113:29-Bishara SE, Khadivi P, Jakobsen JR. Changes in tooth size-arch length relationships from the deciduous to the permanent dentition: a longitudinal study. *Am J Orthod Dentofacial Orthop*. 1995, 108:607–13. 10.1016/S0889-5406(95)70006-4.