



# Major approaches to ozone therapy in endodontic treatments for bone infections and necrosis: a systematic review

Maria Vitória da Costa Alves Azevedo<sup>1</sup>, Vitória Rodrigues Nunes<sup>1</sup>, Guilherme Fávoro Sbrogio<sup>1</sup>, Ana Paula Bernardes da Rosa<sup>1,2\*</sup>

<sup>1</sup> UNORTE - University Center of Northern São Paulo, Dentistry department, São José do Rio Preto, São Paulo, Brazil.

<sup>2</sup> UNIPOS - Post graduate and continuing education, Dentistry department, São José do Rio Preto, São Paulo, Brazil.

\*Corresponding author: Profa. Me. Ana Paula Bernardes da Rosa. Unorte/Unipos – Graduate and Postgraduate education, Dentistry department, São José do Rio Preto, São Paulo, Brazil.

E-mail: [implantesecia@terra.com.br](mailto:implantesecia@terra.com.br)

DOI: <https://doi.org/10.54448/mdnt22S611>

Received: 08-28-2022; Revised: 10-28-2022; Accepted: 11-29-2022; Published: 12-03-2022; MedNEXT-id: e22S611

## Abstract

**Introduction:** The bacterium *Staphylococcus aureus* is, in most cases, the agent of the disease. Thus, inflammation of the bone marrow can cause compression of the bone tissue walls and decrease or blockage of blood supply in the region's blood vessels, which can induce bone necrosis. Clinical studies have demonstrated the efficiency of ozone therapy in the treatment of peritonitis, infected wounds, and advanced ischemic disease. **Objective:** It was demonstrate the main scientific findings of the use of antiseptic ozone therapy in endodontic treatment. **Methods:** The research was carried out from July to October 2022 in Scopus, PubMed, Science Direct, Scielo, and Google Scholar databases. The quality of the studies was based on the GRADE instrument and the risk of bias was analyzed according to the Cochrane instrument. **Results and Conclusion:** A total of 127 articles were found, and 57 articles were evaluated and 29 were included in this systematic review. Considering the Cochrane tool for risk of bias, the overall assessment resulted in 10 studies with a high risk of bias and 28 studies that did not meet GRADE. Most studies showed homogeneity in their results, with  $I^2 = 96.8\% > 50\%$ . Ozone therapy is scientifically proven and demonstrated in this work, it proved to be effective for tissue repair and the prevention and treatment of bone necrosis. It was observed that patients undergoing chemotherapy, radiotherapy, and antiresorptive drugs are more affected by bone necrosis. It was also observed the importance of the patient feeling that the treatment works and is restoring his ability to reinvent himself and adapt to his social environment. Treatments should not only be based on established numbers and protocols,

without analyzing the specific sensations and perceptions of each patient with their lived reality.

**Keywords:** Ozone therapy. Infected wounds. Bone necrosis. Endodontic treatment.

## Introduction

The most common bone necrosis of the oral cavity is drug-induced necrosis, osteoradionecrosis, and osteomyelitis [1]. Drug-induced bone necrosis establishes itself in the oral cavity as a form of exposed necrotic bone, for at least eight weeks, and is usually accompanied by pain, swelling of the oral mucosa, tooth mobility, erythema, and/or infections. It is related to therapies for the treatment of hypercalcemia, and osteoporosis and, mainly, to prevent bone metastasis from malignant tumors [2]. Such drug-based treatments, mainly anti-resorptive ones are bisphosphonates and denosumab.

In this context, patients who receive radiotherapy, as a form of treatment against cancer, are greatly affected by osteoradionecrosis, and radiation can cause bone devitalization [2,3]. The bone becomes hypocellular, hypovascular, and hypoxic, which promotes ulceration, tissue necrosis, trismus, buccal fistula, and necrotic bone exposure, accompanied by pain and paresthesia [3].

Also, conditions such as osteomyelitis can also cause osteonecrosis. The former is related to inflammation of the bone tissue, caused especially by pyogenic bacteria, responsible for the presence of purulent secretion. The bacterium *Staphylococcus aureus* is, in most cases, the agent of the disease. Thus,

inflammation of the bone marrow can cause compression of the bone tissue walls and decrease or blockage of blood supply in the region's blood vessels, which can induce bone necrosis [2,4].

Several treatments are proposed in the literature hyperbaric oxygen therapy, laser, and surgery to remove the necrotic area, with results that are not entirely satisfactory. Complementary treatments that benefit the improvement of these signs and symptoms are extremely important. Among them, ozone therapy stands out. The treatment mentioned above is a chemical compound formed by three oxygen atoms (O<sub>3</sub>), which consists of the connection of an oxygen molecule (O<sub>2</sub>) with an oxygen atom (O) [3]. It is indicated in the following situations: modulation of the immune system and induction of interferon proliferation, tumor necrosis factor, and interleukin [1,5].

Furthermore, clinical studies have demonstrated the efficiency of ozone therapy in the treatment of peritonitis, infected wounds, and advanced ischemic disease. It has an antimicrobial effect, acts on the immune system, and induction of revascularization in cases of irradiated patients and patients submitted to invasive dental procedures, such as extraction [6,7]. Ozone is also widely recognized as one of the best bactericides, antivirals, and antifungals, its beneficial effect on wound healing can be considered due to decreasing bacterial infection and improving dermal wound healing [8,9].

Therefore, the present study aimed, through a systematic review, to demonstrate the main scientific findings of the use of antiseptic ozone therapy in endodontic treatment.

## Methods

### Study Design

The rules of the Systematic Review-PRISMA Platform (Transparent reporting of systematic reviews and meta-analysis - <http://www.prisma-statement.org/>) were followed [10].

### Data sources and research strategy

The search strategies for this systematic review were based on the keywords (MeSH Terms): "*Ozone therapy. Infected wounds. Bone necrosis. Endodontic treatment*". The research was carried out from July to October 2022 and developed based on Scopus, PubMed, Science Direct, Scielo, and Google Scholar. Also, a combination of the keywords with the booleans "OR", "AND", and the operator "NOT" were used to target the scientific articles of interest.

### Study Quality and Bias Risk

The quality of the studies was based on the GRADE instrument [11] and the risk of bias was analyzed according to the Cochrane instrument [12].

## Results and Discussion

A total of 127 articles were found. Initially, duplication of articles was excluded. After this process, the abstracts were evaluated and a new exclusion was performed, removing the articles that did not address the theme of this article. In total, 57 articles were fully evaluated and 29 were included and evaluated in this systematic review. Considering the Cochrane tool for risk of bias, the overall assessment resulted in 10 studies with a high risk of bias and 28 studies that did not meet GRADE. Most studies showed homogeneity in their results, with  $I^2 = 96.8\% > 50\%$  (Figure 1).

**Figure 1.** Flow Chart of Study Eligibility (Systematic Review).

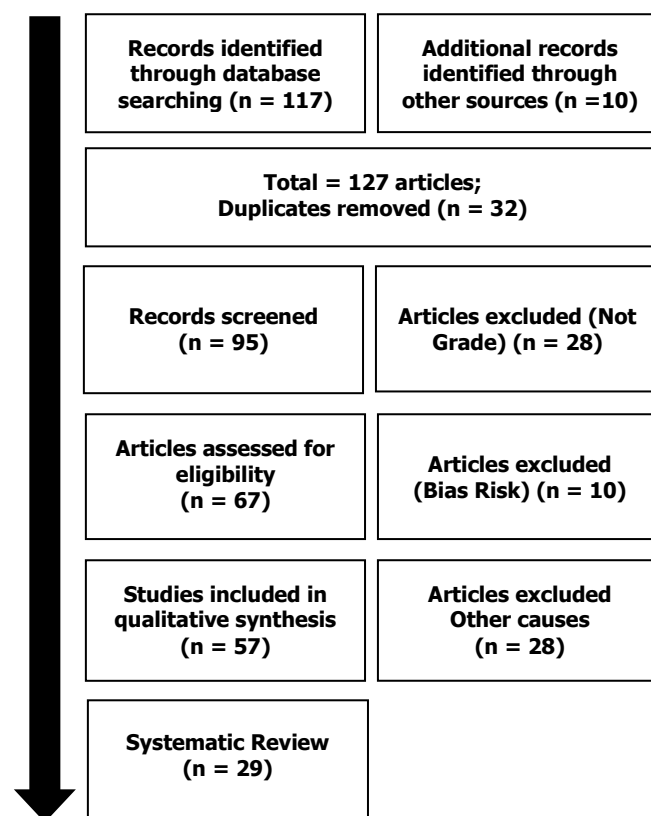
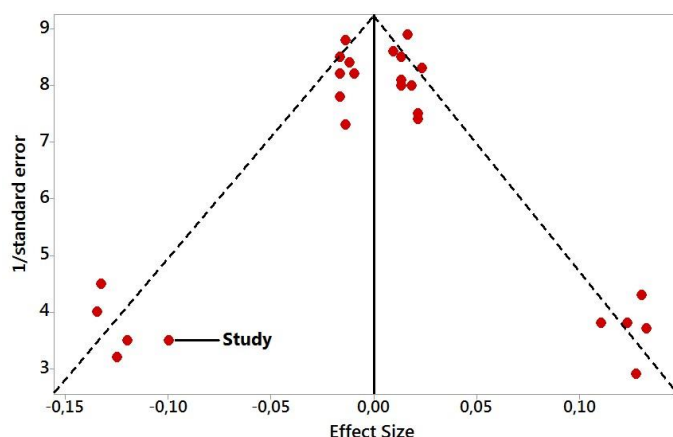


Figure 2 presents the results of the risk of bias in the studies using the Funnel Plot, through the calculation of the Effect Size (Cohen's Test). The sample size was determined indirectly by the inverse of the standard error. The number of clinical studies evaluated was n=29. The graph showed symmetric behavior, not suggesting a significant risk of bias in studies with small sample sizes, which are shown at the bottom of the graph.

**Figure 2.** The symmetric funnel plot does not suggest a risk of bias between the small sample size studies that are shown at the bottom of the graph (N=29 studies).



Several articles demonstrated the effectiveness of ozone therapy in bone necrosis, in particular, osteomyelitis and drug necrosis [1-3]. Most of these necroses are sequelae of the treatment of malignant tumors. Whatever it is, patient compliance is critical. Therefore, as important as the treatment is his quality of life in the face of the entire healthcare process [13].

Because of these aspects, the patient becomes a coadjuvant in his own life, as it will depend on whether or not the suggested treatment is effective, which will interfere with his quality of life. Thus, it is understood that there is no absolute concept that defines the quality of life of a person or a population [14].

Quality of life is related to the way of understanding and comprehending sensations and meanings attributed by individuals concerning their daily lives and presents a notion of health as "the right to a quality life; health as a right to comprehensive care, with the privilege of promotion and prevention, without prejudice to the recovery and rehabilitation of health conditions; as an expression of the journey of life". Oral health was considered, for the first time, as the quality of life in World War II, when oral well-being was established as a means to assess the individual's suitability for the service [15].

Orofacial conditions, diseases, and pain can have significant impacts on the patient's life, concerning the social and individual level, including normal day-to-day activities, in addition to medical and social conditions that can affect oral health. Health professionals and patients may have different views about the quality of life. Therefore, it is necessary to evaluate oral health and quality of life to know what the individual expects when the professional offers real perceptible improvements [16].

Measuring the impact of oral conditions on quality of life should be part of the assessment of oral health needs because clinical indicators alone cannot describe

the satisfaction or symptoms of dental patients or their ability to perform daily activities. Since these indicators are related to the presence or absence of pathological factors, not to perceptions, of improvement or not, seen by patients [17].

Quantifying this perception of quality of life by the patient can be observed through the Oral Health Impact Profile 14 (OHIP14) questionnaire. It is a 14-item questionnaire designed to assess self-reports of functional limitation, discomfort, and disability attributed to oral conditions. It is derived from an original extended version of 49 items based on a theoretical model developed by the World Health Organization (WHO) and adapted for oral health. In this model, the consequences of oral pathologies are hierarchically linked from a biological level, damage to physical health, to a behavioral level, functional limitation, discomfort, and disability, and finally, to a social level, which refers to the difficulties of maintaining the same routine as before the established problem. The OHIP - 14, despite being a short questionnaire, is reliable; sensitive to changes; and has adequate cross-cultural consistency. Its application in patients with signs and symptoms of orofacial pain and temporomandibular disorders has also been widely described by many authors, who concluded that OHIP - 14 may play a role in predicting clinical deterioration in these patients [18,19].

Therefore, the total elimination of microorganisms from the region of infected root canals has been a great and constant concern in the list of Endodontic treatments, demonstrated by several studies that, in the end, evaluated the great action of endodontic instruments, the chemical substances used, the irrigation/aspiration and medication introduced intracranially. Even today, the best and safest method to be used to decontaminate the root canal of the endodontic system is thorough and complete sanitation, since all microorganisms that are present in necrotic root canals cannot be reached. by all host defense cells [20].

The well-conducted chemical-surgical preparation significantly reduces the predominant microorganisms in the root canal. However, persistent microorganisms survive, not only due to the limitation of endodontic surgery in removing them from anatomical complexities but also due to the presence of some nutrients that are capable of favoring the real growth of these microorganisms in a residual form, restoring the possibility of contamination of the pulp space. and periapical tissues [21,22].

In search for some alternatives, ozone therapy has been explored in Medicine and Dentistry as a procedure for therapeutic use in the treatment of many diseases at the stage in which they are classified as acute and

chronic [23]. Ozone, being an allotropic form of oxygen, is the second element with oxidative power in nature, as it has a high and proven antimicrobial action, acting mainly in enhancing the polyunsaturated fatty acids of the bacterial cell membrane. Therefore, it produces an increase in the synthesis of ATP (adenosine triphosphate) and 2,3-diphosphoglycerate, consequently increasing the supply of oxygen to the tissues, in this way the action of ozone, directly and indirectly, modulates the relationship of the patient's immune system, thus improving the body's response to the etiologic agent. It should be clarified that the differential factor is due to the ability of the O<sub>3</sub> molecule to stimulate biological effects, encouraging tissue repair, healing, and return of the tooth to its natural function [24].

Concerning all these attributions, it is understood that ozone thus presents a great potential to be inserted in endodontic therapy, by requesting and incorporating the two requirements necessary for any substance for endodontic use antimicrobial action par excellence and biocompatibility [25,26].

Canal preparation is potentially responsible for microbial control, thus having the ability to reduce the number of bacterial cells by up to 90%. However, concerning the anatomical complexities of the endodontic system, they end up limiting the effectiveness of disinfection. Chemical substances are powerful and capable of becoming auxiliary to permeate the channel system, thus breaking the dynamism of the microbial ecosystem of the channel, and becoming the focus of great interest. Many issues related to the pathogenesis of the periapical lesion are still unknown and require further clarification [27].

When ozone is administered under controlled therapeutic conditions, the body does not recognize the gas as a foreign agent, but rather as a complement to a protection mechanism that is peculiar to it in the activation of antibodies, which produces an immune response against pathogenic microorganisms. The stimulatory action of ozone and that this fact begins in the erythrocytes, and the cycle of Anaerobic Glycolysis provides an increase in the synthesis of diphosphoglycerate. This enzyme is then responsible for breaking the bond between oxygen and hemoglobin, thus releasing oxygen to the tissues. Of this released oxygen, about 95 to 98% is converted to glucose-independent ATP. This extra production of ATP does not depend on the presence of glucose in the system, as occurs in the Krebs Cycle. This fact can be seen as an increase in total cellular metabolism. From 2 to 5% of the oxygen released is converted into free radicals, the most common being Reactive Oxygen Species, including singlet oxygen, hydrogen peroxide, hydroxyl radical,

alkoxyl radical, and peroxy radical, among others present. These ROS, when released in the body, produce an effect of acute and generalized oxidative stress with a potent antimicrobial effect due to the oxidizing action of ozone on the polyunsaturated fatty acids of the present bacterial cell membrane [28].

Also, for microorganisms, ozone will act on the cell membrane, thus promoting its rupture and consequent lysis of the cell wall, thanks to its action on polyunsaturated fatty acids. Due to this very specific and potent action, there are practically no reports of bacterial resistance to the action of ozone [29]. Although ozone and hydrogen peroxide are considered toxic in their pure state, separated into therapeutic doses, they have demonstrated their safety and effect. Its purpose makes the chance of an inappropriate action unfeasible, especially due to the nonpressure of the antioxidant defenses. But, there may be some adverse actions. To prevent this toxicity and provide adequate oxidative stress, the operator must pay attention to doses in which the application stays within the normal range, according to the time of the patient's problem and his systemic state [29].

## Conclusion

Ozone therapy is scientifically proven and demonstrated in this work, it proved to be effective for tissue repair and the prevention and treatment of bone necrosis. It was observed that patients undergoing chemotherapy, radiotherapy, and antiresorptive drugs are more affected by bone necrosis. It was also observed the importance of the patient feeling that the treatment works and is restoring his ability to reinvent himself and adapt to his social environment. Treatments should not only be based on established numbers and protocols, without analyzing the specific sensations and perceptions of each patient with their life reality.

## Acknowledgement

Not applicable.

## Ethics approval

Not applicable.

## Funding

Not applicable.

## Data sharing statement

No additional data are available.

## Conflict of interest

The authors declare no conflict of interest.



## Similarity check

It was applied by Ithenticate@.

## About the License

© The authors (s) 2021. The text of this article is open access and licensed under a Creative Commons Attribution 4.0 International License.

## References

1. Nunes IA, Novais TM, Garcia PP, Silva WS, Tavares RJ, Rizzi CC, Carvalho CN, Filho EM. Antimicrobial action of ozonated water and photodynamic therapy with sonic activation in root canals infected with *Enterococcus faecalis*. *J Clin Exp Dent*. 2022 Jun 1;14(6):e486-e491. doi: 10.4317/jced.57909.
2. Sinha N, Asthana G, Parmar G, Langaliya A, Shah J, Kumbhar A, Singh B. Evaluation of Ozone Therapy in Endodontic Treatment of Teeth with Necrotic Pulp and Apical Periodontitis: A Randomized Clinical Trial. *J Endod*. 2021 Dec;47(12):1820-1828. doi: 10.1016/j.joen.2021.09.006.
3. Silva EJNL, Prado MC, Soares DN, Hecksher F, Martins JNR, Fidalgo TKS. The effect of ozone therapy in root canal disinfection: a systematic review. *Int Endod J*. 2020 Mar;53(3):317-332. doi: 10.1111/iej.13229.
4. Makeeva MK, Daurova FY, Byakova SF, Turkina AY. Treatment of an Endo-Perio Lesion with Ozone Gas in a Patient with Aggressive Periodontitis: A Clinical Case Report and Literature Review. *Clin Cosmet Investig Dent*. 2020 Oct 28;12:447-464. doi: 10.2147/CCIDE.S267933.
5. Sen S, Sen S. Ozone therapy a new vista in dentistry: integrated review. *Med Gas Res*. 2020 Oct-Dec;10(4):189-192. doi: 10.4103/2045-9912.304226.
6. A SR, Reddy N, Dinapadu S, Reddy M, Pasari S. Role of ozone therapy in minimal intervention dentistry and endodontics - a review. *J Int Oral Health*. 2013 Jun;5(3):1028. Epub 2013 Jun 23. PMID: 24155611; PMCID: PMC3769872.
7. Halbauer K, Prskalo K, Janković B, Tarle Z, Pandurić V, Kalenić S. Efficacy of ozone on microorganisms in the tooth root canal. *Coll Antropol*. 2013 Mar;37(1):101-7.
8. Vincent JL, Lartigau G. A propos de l'ozone [Ozone]. *Rev Fr Odontostomatol*. 1971 Aug-Sep;18(7):839-58.
9. Brignardello-Petersen R. Insufficient evidence regarding the effects of ozone when used as a disinfectant in root canal therapy. *J Am Dent Assoc*. 2020 May;151(5):e43. doi: 10.1016/j.adaj.2019.12.007.
10. The PRISMA 2020 statement: an updated guideline for reporting systematic reviews. *BMJ* 2021; 372 doi: <https://doi.org/10.1136/bmj.n71>
11. H Balshem H, Grade guidelines: 3 rating the quality of evidence. *Journal of Clinical Epidemiology*, Maryland Heights, 64 (4) (2011) 401-406.
12. Higgins, S Green, Cochrane Handbook for Systematic Reviews of Interventions. Version 5.1.0 [updated March 2011]. The Cochrane Collaboration; 2011.
13. Boch T, Tennert C, Vach K, Al-Ahmad A, Hellwig E, Polydorou O (2016) Effect of gaseous ozone on *Enterococcus faecalis* biofilm-an in vitro study. *Clinical Oral Investigations*, 20, 1733–9.
14. Case PD, Bird PS, Kahler WA, George R, Walsh LJ. Treatment of root canal biofilms of *Enterococcus faecalis* with ozone gas and passive ultrasound activation. *Journal of Endodontics*, 2012, 38, 523–6.
15. Rojas-Valencia MN. Research on ozone application as disinfectant and action mechanisms on wastewater microorganisms. In: Mendez-Vilas A, ed. *Science Against Microbial Pathogens: Communicating Current Research and Technological Advances*. Badajoz: Formatex, 2011, pp. 263–71.
16. Junior OO, Lages GC (2012) Ozone therapy for lumbosacral pain. *Revista Dor* 13, 261–70.
17. Hubbezoglu I, Zan R, Tunc T, Sumer Z (2014) Antibacterial efficacy of aqueous ozone in root canals infected by *Enterococcus faecalis*. *Jundishapur Journal of Microbiology* 7, e11411.
18. Cunningham SJ, Garratt AM, Hunt NP. Development of a condition-specific quality of life measure for patients with dentofacial deformity: II. Validity and responsiveness testing. *Community Dent Oral Epidemiol*. 2002;30(2):81–90.
19. Montero-Martin J, Bravo-Pérez M, Albaladejo-Martínez A, Hernández-Martin LA, Rosel-Gallardo EM. Validation the Oral Health Impact Profile (OHIP-14sp) for adults in Spain. *Med Oral Patol Oral Cir Bucal*. 2009;14(1).
20. Huth KC, Quirling M, Maier S, et al. Effectiveness of ozone against endodontopathogenic microorganisms in a root canal biofilm model. *International Endodontic Journal*, 2009, 42, 3–13.
21. Kist S, Kollmuss M, Jung J, Schubert S, Hickel

- R, Huth KC (2017) Comparison of ozone gas and sodium hypochlorite/chlorhexidine two-visit disinfection protocols in treating apical periodontitis: a randomized controlled clinical trial. *Clinical Oral Investigations* 21, 995–1005.
22. Kaya BU, Kececi AD, Guldaz HE, et al. (2014) Efficacy of endodontic applications of ozone and low-temperature atmospheric pressure plasma on root canals infected with *Enterococcus faecalis*. *Letters in Applied Microbiology* 58, 8–15.
23. Nagayoshi M, Kitamura C, Fukuizumi T, Nishihara T, Terashita M (2004) Antimicrobial effect of ozonated water on bacteria invading dentinal tubules. *Journal of Endodontics* 30, 778–81.
24. Hyslop PA, Hinshaw DB, Halsey WA Jr, et al. (1988) Mechanisms of oxidant-mediated cell injury. The glycolytic and mitochondrial pathways of ADP phosphorylation are major intracellular targets inactivated by hydrogen peroxide. *The Journal of Biological Chemistry* 263, 1665–75.
25. Filippi A (2001) The effects of ozonized water on epithelial wound healing (in German). *Deutsche Zahnärztliche Zeitschrift* 56, 104–8.
26. Noites R, Pina-Vaz C, Rocha R, Carvalho MF, Goncalves A, Pina-Vaz I (2014) Synergistic antimicrobial action of chlorhexidine and ozone in endodontic treatment. *BioMed Research International* 2014, 592423.
27. Silva EJNL, Prado MC, Soares DN, Hecksher F, Martins JNR, Fidalgo TKS. The effect of ozone therapy in root canal disinfection: a systematic review. *Int Endod J*. 2020 Mar;53(3):317-332. doi: 10.1111/iej.13229.
28. Almadi K, Alkahtany M, Alamam Y, Alaql F, Alaql A, Almutairi M, Thafrah SMB. Influence of Propolis, Ozone and Photodynamic therapy in root canal disinfection on resin bond strength to radicular dentin. *Photodiagnosis Photodyn Ther*. 2021 Mar;33:102131. doi: 10.1016/j.pdpdt.2020.102131.
29. Kaur A, Bhavikatti SK, Das SS, Khanna S, Jain M, Kaur A. Efficacy of Ozonised Water and 0.2% Chlorhexidine Gluconate in the Management of Chronic Periodontitis when Used as an Irrigant in Conjugation with Phase I Therapy. *J Contemp Dent Pract*. 2019 Mar 1;20(3):318-323.

