



State of the art research of immediate loading technique and single dental implants: a systematic review

Pedro Augusto Garcia Franco^{1*}, Deivid Gustavo Aparecido Fernandes de Lima¹, Johan Victor Nicolladelli Carvalho¹, Elias Naim Kassis^{1,2}

¹ UNORTE - University Center of Northern São Paulo, Dentistry department, Sao Jose do Rio Preto, Sao Paulo, Brazil.

² UNIPOS - Post graduate and continuing education, Dentistry department, Sao Jose do Rio Preto, Sao Paulo, Brazil.

*Corresponding author: Pedro Augusto Garcia Franco.

Unorte/Unipos – Graduate and Postgraduate education, Dentistry department, Sao Jose do Rio Preto, Sao Paulo, Brazil.

E-mail: pedro.augustonegocios@hotmail.com

DOI: <https://doi.org/10.54448/mdnt22S504>

Received: 05-09-2022; Revised: 07-18-2022; Accepted: 08-04-2022; Published: 08-26-2022; MedNEXT-id: e22S504

Abstract

Introduction: The use of dental implants in the rehabilitation of partially or edentulous patients followed an implant submersion protocol for 3-6 months during osseointegration. Currently, the immediate loading implant (ILI) is considered to offer many advantages for the patient and the clinician, including maintaining the height of the soft tissues and increasing the peri-implant bone density. Also, ILI is associated with reductions in patient pain, time, and material, with success rates of 95 to 100% being reported. **Objective:** To demonstrate the clinical success indexes of the immediate loading technique, to present the criteria of indication and the follow-up of the procedures.

Methods: The rules of the Systematic Review-PRISMA Platform were followed. The research was carried out in February to May 2022 and developed based on Scopus, PubMed, Science Direct, Scielo, and Google Scholar. The quality of the studies was based on the GRADE instrument and the risk of bias was analyzed according to the Cochrane instrument. **Results and Conclusion:** The analysis of the bibliography obtained showed that the success rates with the ILI technique are compatible with those of the late load, as long as certain guidelines are followed that were divided into factors related to the patient, the surgical technique, and the implant, the prosthesis and to aesthetics. The high success rate is a consequence of the correct surgical and prosthetic planning, and harmony between the implant system, patient, and dental surgeon. As for the region, currently, it can be said that ILI in total jaw rehabilitation is a procedure with high success rates that should and can be applied in all cases where the technique is efficient

to provide adequate primary stability to the implants. Therefore, the technical improvement of the dentist becomes the main condition for this philosophy to be applied.

Keywords: Immediate loading implants. Immediate loading technique. Single dental implants. Implantology. Clinical trials.

Introduction

The use of dental implants in the rehabilitation of partially or edentulous patients followed an implant submersion protocol for 3-6 months during osseointegration (OI), to reduce the risk of implant failure caused by movements in the interface [1]. In this context, subsequent improvements in the surgical technique as an implant structure and masticatory forces have led to the evidence that immediate loading procedures can be successful [2].

In this sense, currently, the immediate loading implant (ILI) is considered to offer many advantages for the patient and the clinician, including maintaining the height of the soft tissues and increasing the peri-implant bone density [3]. Also, ILI is associated with reductions in patient pain, time, and material, with success rates of 95 to 100% being reported [4].

Thus, the option of ILI right after surgery is indicated when the implants are placed with high insertion torques in bones of good quality, volume, and without bruxism. Still in this sense, some studies have suggested that patients have generally acceptable or controlled oral hygiene, patients would be available for the postoperative period, and patients with partially

reentrant arches so that there is no need for an increase in hard tissue in the posterior mandible [5].

Also, smoking has been shown to have a deleterious effect on OI, however many studies have not revealed that smoking is a significant predictor of ILI. Furthermore, the results of implant surgery can be compromised by circulatory, respiratory, and hormonal factors such as diabetes mellitus, pregnancy, alcoholism, immunodeficiency states, and vitamin D-dependent rickets [6].

In the historical and literary context, the first studies of implant follow-up, in the long term, constituted the scientific foundation of modern implant dentistry. Both for a two-stage surgical protocol and a single surgical stage protocol, waiting time was required for OI to occur [7,8]. Early loading was identified as a critical factor and, therefore, several waiting times were tested until the establishment of a period of at least three months for the mandible and five to six months for the maxilla [9].

This concept of a healing period, before the implants were subjected to functional load, was based on the knowledge previously available, related to the bone repair of fractures and osteotomies that needed a period of 3 to 6 months before the functional loads could be gradually applied. Also, the objective of that approach was to prevent bacterial infection by exposing the implants to the oral environment, a factor that could negatively interfere with the OI process [10].

Another reason was that premature loading could lead to micro-movements that would result in the encapsulation of the implant by fibrous tissue, a fact that would prevent direct bone apposition as well as that the necrotic bone at the edge of the implant bed would not be able to absorb the loads and should first be replaced with new bone [11,12].

With the advancement of research, even considering the high rates of clinical success of the techniques that advocate late loading, some researchers began to question the possibility of reducing the time for the implants to be loaded, as loading by itself would not prevent the healing process [13]. ILI was defined as the "installation of a prosthetic element on an implant, without OI occurring" [14].

The major disadvantage of the protocol with late loading is the use of temporary prostheses without, in most situations, stability, and retention, generating situations of discomfort; frequent adjustment needs; new surgery to expose the implants, in the case of a two-stage surgical protocol; possible psychological and social problems [15]. In contrast, the ILI concept includes advantages where discomfort, inconvenience of increased surgical time are eliminated as it is a single-

stage procedure [16] and more: splinted implants can decrease the risk of overload in each implant, as it increases the surface area and improves the biomechanical distribution; the patient does not use a removable prosthesis during the initial bone healing phase and thereby increases comfort, function, phonetics, stability and certainly improves psychological factors during this transition period [17].

Thus, the objective of the present study was to demonstrate, through a systematic review, the clinical success indexes of the immediate loading technique, to present the indication criteria and the follow-up of the procedures.

Methods

Study Design

The rules of the Systematic Review-PRISMA Platform (Transparent reporting of systematic reviews and meta-analysis-[HTTP://www.prisma-statement.org/](http://www.prisma-statement.org/)) were followed.

Data sources and research strategy

The search strategies for this systematic review were based on the keywords (MeSH Terms): "*Immediate loading implants. Immediate loading technique. Single dental implants. Implantology. Clinical trials*". The research was carried out in February to May 2022 and developed based on Scopus, PubMed, Science Direct, Scielo, and Google Scholar. Also, a combination of the keywords with the booleans "OR", "AND", and the operator "NOT" were used to target the scientific articles of interest.

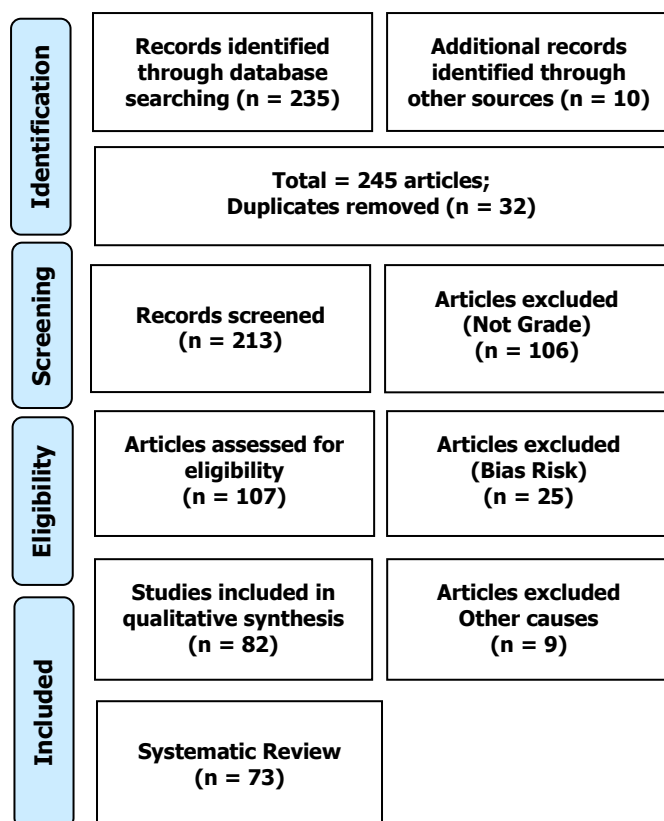
Study Quality and Bias Risk

The quality of the studies was based on the GRADE instrument and the risk of bias was analyzed according to the Cochrane instrument.

Results and Discussion

A total of 245 articles were found. Initially, duplication of articles was excluded. After this process, the abstracts were evaluated and a new exclusion was performed, removing the articles that did not address the theme of this article. In total, 107 articles were fully evaluated and 73 were included and evaluated in this study (Figure 1).

To date, there is a heterogeneity of studies on ILI, and it is still difficult to generate a guideline or consensus through a meta-analysis [58]. Also, it is necessary to conduct randomized clinical studies with longer follow-ups [59,60]. Despite this, due to

Figure 1. Study Eligibility (Systematic Review).

improvements in bioengineering techniques and topography of the implant surface, the ILI technique can be used successfully in many patients [61].

In this context, the success rates for ILI are comparable to the success rates of conventionally loaded implants. However, some trends suggest that ILI has a shorter survival time than conventionally loaded implants. In this scenario, a high degree of insertion torque is a prerequisite for a successful procedure [62].

Most of the initial studies reported that the best results would be in the anterior mandible region [63-65], suggesting that the chosen region should be, strictly, among the mental foramina. As for the types of prostheses that received ILI, studies were carried out using implant-retained, mucus-supported mandibular overdentures and fixed prostheses [66-69]. Some authors chose to leave a part of the implants submerged so that they would heal conventionally (late loading), in case the implants with ILI failed, having the guarantee that they would not harm the final rehabilitation works. This was also important so that they could compare the two techniques, in terms of results and predictability [68,69].

But it was also demonstrated that the technique is predictable in both arches [70], as well as in the posterior region, and concluded that the best results would be related to regions with better bone qualities [71]. The follow-up times, with the respective success rates, were high and varied between 18 months, with

100% [63] to 8.6 years, with 96.7% success that this factor influenced the results.

In this sense, prior preparation can reduce time and improve patient comfort. Thus, a randomized controlled study with 20 patients analyzed immediate functional versus non-functional loads with posterior mandible restorations for marginal bone defects, implant success/survival, and patient satisfaction. A questionnaire with visual analog scales was used to assess patient satisfaction. After 36 months, data were assessed for 9 patients (21 implants) in the study group (immediate functional load) and 10 patients (31 implants) in the control group (immediate non-functional load). One implant in the control group was lost, so the implant's overall success and survival rate was 98.2%. Marginal bone defects were consistent with previous studies and comparable in both groups. Periotest values did not change significantly from the beginning and at 12 months of follow-up. Patient satisfaction was high and did not involve significant intergroup differences. Therefore, both types of immediate provisional restorations are viable in selected patients [72].

Another study explored the viability and short-term clinical results of ILI with fixed temporary bridges (2 to 4 teeth) through a complete digital workflow and assessed the three-dimensional (3D) deviation of the fingerprint compared to the traditional printing method. A total of 31 partially edentulous patients (16 women and 15 men) were recruited for this study. Fingerprints were taken immediately after implant placement, and temporary splint bridges supported by the implant were manufactured using a fully digital approach (no model) and delivered within 24 hours. Definitive restorations were completed 4 months after surgery using the traditional printing technique. 3D printing deviations were analyzed by comparing digital and conventional printing methods. Seventy-four implants were surgically placed and immediately loaded with 34 temporary bridges manufactured using a completely digital approach. The fingerprint deviation compared to the traditional printing method was $27.43 \pm 13.47 \mu\text{m}$. The time costs for the chair and laboratory side were 32.55 ± 4.73 and 69.30 ± 10.87 minutes, respectively. The marginal bone changes were -1.58 mm and -1.69 mm at 4 and 12 months after surgery. The implants had a survival rate of 100% in the follow-up period of 1 year. Immediate loading of multiple implants in partially edentulous patients (2-4 teeth) with a completely digital approach is clinically applicable. The 3D discrepancy between fingerprint and traditional is within the acceptable clinical range [58].

Also, a 24-month randomized controlled trial investigated whether the survival of a single median

implant placed in the toothless jaws to retain a full denture is not compromised by immediate loading. Each of the 158 patients who received an implant was randomly assigned to either the immediate load group ($n = 81$) or the delayed load group ($n = 77$). Remembrance visits were performed 1 month after implant placement (only for the delayed loading group) and 1, 4, 12, and 24 months after implant loading. Nine implants failed in the immediate loading group, all within the first 3 months of implant loading, and 1 implant failed in the delayed loading group before loading. Non-inferiority of the implant survival of the immediate load group, in comparison with the delayed load group, could not be shown ($p = 0.81$). Consistent with this result, a secondary analysis with Fisher's exact test revealed that the difference observed in implant survival between treatment groups was statistically significant ($p = 0.019$). The most frequent prosthetic complications and maintenance interventions in the jaw were retention adjustments, prosthesis fractures, pressure ulcers, and matrix changes. There was only 1 statistically significant difference between the groups in the parameter "fracture of the base of the prosthesis in the area of fixation of the ball" ($p = 0.007$). Thus, the results indicated that the immediate loading of a single implant in the toothless jaws reveals inferior survival than the delay in loading and, therefore, should be considered only in exceptional cases [59].

In general, the first period of studies on ILI had consistent scientific documentation, with long follow-up periods, showing different options for rehabilitation. In their observations, they suggested that some criteria, such as improved bone quality, use of the crossed arch, and position in implant tripodism would improve the results. They also demonstrated that the advantages of IC include immediate function and aesthetics, shortened treatment time, and greater comfort for the patient because they do not need to use uncomfortable removable prostheses, thereby improving the acceptance of rehabilitative treatment [64,65].

The analysis of the bibliography obtained showed that the success rates with the ILI technique are compatible with those of the late load, as long as certain guidelines are followed that were divided into factors related to the patient, the surgical technique, and the implant, the prosthesis and to aesthetics. The high success rate is a consequence of the correct surgical and prosthetic planning, and harmony between the implant system, patient, and dentist [70].

Immediate loading is a predictable technique, as long as several clinical criteria are followed. Patient care, such as control of functions, bone quality, and quantity. In surgical technique, it is important to achieve initial stability and reduce surgical trauma, as well as the

professional's skill and experience. Primary and secondary stability are biomechanical characteristics directly related to the success of OI implants, both for the delayed loading technique and the immediate loading technique. Specific values of primary stability are determining and essential factors to enable the clinical practice of the technique. Achieving primary stability is a key factor for applying the immediate load successfully in the short and long term. Different areas to be rehabilitated have different biological, anatomical, and mechanical characteristics [71,72].

As for the factors related to the implants, macro and micro surfaces are important. Several implant designs available, assist the surgeon to achieve high success rates and achieve excellent clinical results, reducing failures and losses by optimizing initial stability. And in this regard, surface treatment is not a necessary condition for the success of immediate loading, but it can accelerate the OI process, acting on secondary stability, making it desirable, as the treatment time would be shorter and the OI punctuated [72]. As for the shape, threaded, tapered implants with short thread pitch, the trapezoidal shape is preferred. Length ≥ 10 mm. Diameter ≥ 3.75 mm. As for the number, in partial cases it should be 1 for each missing element; in total jaws, from 6 to 8 implants; in total mandibles a minimum of 3 to 4 implants. Safer connections between implant and prosthesis, in the sense of not loosening, are more desirable [72].

The knowledge of the aesthetic fundamentals in natural dentition, combined with the biology of the surrounding tissues, admits to relating them to aesthetic implant dentistry. It is observed that much more than the technical capacity of the surgeon and the prosthetist, the preservation of the alveolar ridge, and the recognition of the biological behavior of peri-implant tissues, determine the predictability of the treatment. The correct selection of the patient is one of the most important factors for the success of the immediate loading technique, especially in aesthetic areas, where the establishment of bone and gingival architecture, close to normal standards, is one of the most desired factors in implantology [72].

As for prosthetic care, there must be a scheme to ensure that the forces are located along the tooth axis, and for this, care was suggested with the positioning of the implant, absence of cantilevers, narrow occlusal tables, and in cases of unitary, there should be no occlusal contact and there are controversies about the need for bicorticalization. As for the region, it can be said that in total rehabilitation of the mandibles, the ILI is a procedure with high success rates that should and can be applied in all cases where the technique is efficient to provide adequate primary stability to the

implants. Therefore, the technical improvement of the dentist becomes the main condition for this philosophy to be applied [71].

As for the maxilla, its approach is complex, due to the differences in the resorption pattern, compared to the mandible, the presence of anatomical repairs that may offer limitations to the placement of implants, as well as the aesthetic issue. The planning must be judicious according to the selection rules to be directed to a certain form of the clinical approach, which meets the aesthetic and functional needs of each case [71].

In unit cases, it is important to take special care with the biomechanical characteristics of the implants, an occlusal scheme that avoids overload, as splinting is not possible, but we must also be concerned with aesthetic aspects in cases of compromised aesthetics. In addition, immediate placement minimizes the emotional trauma of losing an anterior tooth and eliminates the need for temporary removable dentures. In partial cases, care should be taken to obtain primary stability, splendor, disposition, and quantity of implants, care for surgery, patient and implant, and occlusion [72].

Due to its widespread use over the years and many scientific works, the use of the immediate loading technique should be considered as an option in the daily routine of the clinic, as long as the determining factors reported are observed and the surgeon has organization and mastery in the area. subject, but the results are not superior to those of late loading [72].

Conclusion

The analysis of the bibliography obtained showed that the success rates with the ILI technique are compatible with those of the late load, as long as certain guidelines are followed that were divided into factors related to the patient, the surgical technique, and the implant, the prosthesis and to aesthetics. The high success rate is a consequence of the correct surgical and prosthetic planning, and harmony between the implant system, patient, and dental surgeon. As for the region, currently, it can be said that ILI in total jaw rehabilitation is a procedure with high success rates that should and can be applied in all cases where the technique is efficient to provide adequate primary stability to the implants. Therefore, the technical improvement of the dentist becomes the main condition for this philosophy to be applied.

Acknowledgement

Not applicable.

Funding

Not applicable.

Ethics approval

Not applicable.

Informed consent

Not applicable.

Data sharing statement

No additional data are available.

Conflict of interest

The authors declare no conflict of interest.

Similarity check

It was applied by Ithenticate@.

About the License

© The authors (s) 2022. The text of this article is open access and licensed under a Creative Commons Attribution 4.0 International License.

References

1. Zhou W, Gallucci GO, Chen S, Buser D, Hamilton A. Placement and Loading Protocols for Single Implants in Different Locations: A Systematic Review. *Int J Oral Maxillofac Implants*. 2021 Jul-Aug;36(4):e72-e89. doi: 10.11607/jomi.8750. PMID: 34411212.
2. Cercadillo-Ibarguren I, Sánchez-Torres A, Figueiredo R, Schwarz F, Gay-Escoda C, Valmaseda-castellón E. Immediately loaded implant-supported full-arches: Peri-implant status after 1-9years in a private practice. *J Dent*. 2017 Sep 28. pii: S0300-5712(17)30240-3. doi: 10.1016/j.jdent.2017.09.014.
3. Tuminelli FJ, Walter LR, Neugarten J, Bedrossian E. Immediate loading of zygomatic implants: A systematic review of implant survival, prosthesis survival and potential complications. *Eur J Oral Implantol*. 2017;10 Suppl 1:79-87.
4. Giordano F, Esposito M. Immediate loading of fixed prostheses in fully edentulous jaws-1-year follow-up from a single-cohort retrospective study. *Eur J Oral Implantol*. 2017;10(3):339-348.
5. Alfadda SA, Furzer JE. Cost minimization analysis of a long-term randomized clinical trial of patients treated with immediately loaded implant-supported fixed prosthesis. *Clin Implant Dent Relat Res*. 2017 Sep 21. doi: 10.1111/cid.12542.
6. Henningsen A, Smeets R, Köppen K, Sehner S,

- Kornmann F, Gröbe A, Heiland M, Gerlach T. Immediate loading of subcrestally placed dental implants in anterior and premolar sites. *J Craniomaxillofac Surg.* 2017 Aug 23. pii: S1010-5182(17)30277-9. doi: 10.1016/j.jcms.2017.08.017.
7. Sugiura T, Yamamoto K, Horita S, Murakami K, Tsutsumi S, Kirita T. Effects of implant tilting and the loading direction on the displacement and micromotion of immediately loaded implants: an in vitro experiment and finite element analysis. *J Periodontal Implant Sci.* 2017 Aug;47(4):251-262. doi: 10.5051/jpis.2017.47.4.251. Epub 2017 Aug 28.
 8. Anitua E. Immediate Loading of Short Implants in Posterior Maxillae: Case Series. *Acta Stomatol Croat.* 2017 Jun;51(2):157-162. doi: 10.15644/asc51/2/10.
 9. Balshi TJ; Wolfinger GJ. Immediate loading of Brånemark implants in edentulous mandibles: a preliminary report. *Implant Dent.*; 1997, 6(2): 83-8.
 10. Balshi SF, Wolfinger GJ, Balshi TJ. A prospective study of immediate functional loading, following the Teeth in a Day protocol: a case series of 55 consecutive edentulous maxillas. *Clin Implant Dent Relat Res*; 2005, 7(1):24-31.
 11. Balshi SF, Wolfinger GJ, Balshi TJ. A retrospective analysis of 44 implants with no rotational primary stability used for fixed prosthesis anchorage. *Int J Oral Maxillofac Implants*; 2007, 22(3): 467-71.
 12. Becker W; Becker BE; Huffstetler S. Early functional loading at 5 days for Brånemark implants placed into edentulous mandibles: a prospective, open-ended, longitudinal study. *J Periodontol*; 2003, 74(5): 695-702.
 13. Branemark P-I, Breine U, Adell R, Hanson BO, Lindström J & Ohlsson A. Intraosseous anchorage of dental prosthesis. I. Experimental studies. *Scandinavian Journal of plastic Reconstructive Surgery*; 1969, 3(2): 81-100.
 14. Branemark P-I, hansson BO, Adell R, Breine U, Lindström J, Hallen O & Ohman H. Osseointegrated implants in the treatment of the edentulous jaws. Experience from a 10 years period. *Scandinavian Journal of Plastic Reconstructive Surgery*; 1977, 16: 1-132.
 15. Calandriello R; Tomatis M; Vallone R., et al. Immediate occlusal loading of single lower molars using Brånemark System Wide-Platform TiUnite implants: an interim report of a prospective open-ended clinical multicenter study. *Clin Implant Dent Relat Res*; 5 (1): 74-80, 2003.
 16. Chiapasco M, Gatti C, Rossi E., et al. Implant retained mandible overdentures with immediate loading. A retrospective multicenter study on 226 consecutives cases. *Clin Oral Implants Res*; 8: 48-57, 1997.
 17. Cochran DL, Morton D, Weber HP. Consensus Statements and Recommended Clinical Procedures Regarding loading Protocols for Endosseous Dental Implants. *J Oral & Maxillofacial Implants*; 2004, 19: 109-113, 2004.
 18. Degidi M, Piatelli A. Immediate functional and non-functional loading of dental implants. A 2 to 60 month follow-up study of 646 titanium implants. *J periodontol*; 74: 225-241, 2003.
 19. Degidi M, Piatelli A, Gehrke P et al. Clinical outcomes of 802 immediately Loaded 2-stage submerged implants with a New Grit-Blasted and acid-etched surface: 12-month follow up. *The international Journal of Oral maxillofacial Implants*; 2006, 1(5): 763-768.
 20. Degidi M, Piatelli A, Lezi G et al. Immediately loaded short implants: analysis of a case of 133 implants. *Quintessence International*; 36 (3): 193-201, 2007^a.
 21. Degidi M, Piatelli A, Lezi G et al. Retrospective study of 200 immediately loaded implants retaining 50 mandibles Overdenture. *Quintessence International*; 2007, 36(4): 281-288.
 22. Degidi M; Lezi G; Scarano A; Piattelli. A Immediately loaded titanium implant with a tissue-stabilizing/maintaining design ('beyond platform switch') retrieved from man after 4 weeks: a histological and histomorphometrical evaluation. A case report. *Clin Oral Implants Res.*; 2008, 19(3):276-82.
 23. Degidi M, Novaes AB, Nardi D. et al. Outcome Analysis of Immediately Placed, Immediately Restored Implants in the Esthetic Area: The Clinical Relevance of Different Interimplant Distances. *J Periodontol.*; 2008, 79(6):1056-1061.
 24. Gallucci GO, Bernard JP, Bertosa M. et al. Immediate loading with fixed screw-retained provisional restorations in edentulous jaws: the pickup technique. *Int J Oral Maxillofacial Implants*; 2004, 19 (4):524-533.
 25. Gallucci GO, Mavropoulos A, Bernard JP. et al. Influence of immediate implant loading on peri-implant soft tissue morphology in the edentulous maxilla. *Int J Oral Maxillofacial Implants*; 2007, 22(4):595-602.
 26. Horiuchi K; Uchida H; Sugimura M. Immediate loading of Branemark System Implants following placement in edentulous patients: A clinical

- report. *Int J. Oral Maxillofacial Implants*; 2000, 15: 824-830.
27. Lekholm U, Zarb. G.A. Patient selection and preparation. In: Branemark, P.I, Zarb, G.A., Albrektsson T. *Tissue-integrated prostheses: Osseointegration in clinical dentistry*. Chicago: Quintessence, p. 199-209, 1985.
28. Lekholm U. Immediate / early loading of oral implants in compromised patients. *Periodontology* 2000; 33: 194-203, 2003.
29. Maló P, Friberg B, Polizzi G. et al. Immediate and Early Function Branemark System Implants Placed in the esthetic Zone: 1 year prospective clinical multicenter study. *Clinical Implant dentistry and related research*; 5(1): 37-46. 2003.
30. Maló P, Rangert B, Nobre M. « All-on-four'' immediate-function concept with Branemark System implants for completely edentulous maxillae: a 1 year retrospective clinical study. *Clin Implant Dent Relat Res*; 7(suppl 1): 88-94, 2005.
31. Morton D, Jeffin R, Weber HP. Immediate restoration and Loading of dental implants: Clinical considerations and Protocols. *The international Journal of Oral maxillofacial Implants*; 19: 103-108, 2004.
32. Randow K; Ericsson I; Nilner K; Petersson A; Glantz PO. Immediate functional loading of Brånemark dental implants. An 18-month clinical follow-up study. *Clin Oral Implants Res.*; 10(1): 8-15, 1999.
33. Rocci A; Martignoni M; Gottlow J. Immediate loading of Brånemark System TiUnite and machined-surface implants in the posterior mandible: a randomized open-ended clinical trial. *Clin Implant Dent Relat Res.*; 5 Suppl 1:57-63, 2003a.
34. Rocci A, Martignoni M, Gottlow J. Immediate loading in maxilla Using Flapless surgery, Implant placed in predetermined position an prefabricated provisional restorations: A retrospective 3 year clinical study. *Clinical Implant Dentistry and related Research*; 1(1): 29-36, 2003b.
35. Schnitman PA, Wohrle OS, Rubenstein JE. Immediate fixed interim prostheses supported by two-stage threaded implants: methodology and result *J Oral Implantol.*, 16(2):96-105, 1990.
36. Schnitman PA, Wohrle PS, Rubenstein JE, et al. Branemark implants immediately loaded with fixed prostheses at implant placement. Ten year results. *Int J Oral Maxillofac Implants*; 1997, 12:495-503.
37. Schroeder A , Van Der Zyper E, Stich H. et al. The reaction of bone, connective tissue and epithelium to endosteal implants with titanium-sprayed surfaces. *J Maxillofac. Surg.*, 1981, 1: 15-25.
38. Skalak R. Biomechanical considerations in osseointegrated prostheses. *J of Prosthetic dentistry*. 1983, 49 (6): 843-848.
39. Spiekermann H, Jansen VK, Richter EJ. A 10-year follow-up study of IMZ and TPS implants in the edentulous mandible using bar-retained overdentures. *Int J Oral Maxillofac Implants*; 1995, 10(2): 231-43.
40. Szmukler- Moncler S, Salama H, Reingewirtz Y et al. Timing of loadind of micromotion on bone-dental implants interface: review of experimental literature. *J Biomed mater Res.*; 1998, 43(2):192-203.
41. Szmukler-Moncler S, Piatelli A, Favero GA. et al. Considerations preliminary to the application of early and immediate loading protocols in dental implantology. *Clin Oral Impl Res.*; 2000, 11(1): 12-25.
42. Tarnow DP, Magner AW, Fletcher P. The effect of the distance from the contact point to the crest of bone on the presence or absence of the interproximal dental papilla. *J periodontol.*; 63(12): 995-6, 1992.
43. Tarnow DP, Emtiaz S & Classi A. Immediate loading of threaded implants at stage 1 surgery in edentulous arches: Tem consecutive case reports with 1- to 5- years date. *International of Oral and maxillofacial Implants*; 12: 319-324, 1997.
44. Tarnow DP, Cho SC, Wallace SS. The effect of interimplant distance on the height of inter-implant bone crest. *J Periodonto.*; 71(4): 546-9, 2000.
45. Tarnow D; Elian N; Fletcher P. et al. Vertical distance from the crest of bone to the height of the interproximal papilla between adjacent implants. *J Periodontol*; 74(12): 1785-8, 2003.
46. Tortamano P, Camargo LO, Veiga J. Critérios clínicos de estabilidade inicial e qualidade óssea para o carregamento imediato de implantes osseointegrados. *Rev. Implant News*; 1(1): 61-65, 2004.
47. Tortamano P, Orie TC, Yamanochi J. et al. Outcomes of Fixed Prostheses supported by Immediately loaded Endosseous Implants. *The international Journal of Oral maxillofacial Implants*; 21(1): 63-70, 2006.
48. Albrektsoon T. Direct bone anchorage of dental implants. *Journal of Prosthetic Dentistry*; 50: 255-261, 1983.
49. Albrektsson T., Branemark P.I., Hanson H.A., Lindström, J. Osseointegration Titanium implants: requirements for ensuring a long-lasting, direct

- bone to implant anchorage in man. *Acta Orthopedic Scandinavian*, 52: 155-170, 1981.
50. Al-Sawai AA, Labib H. Success of immediate loading implants compared to conventionally-loaded implants: a literature review. *J Investig Clin Dent*. 2016 Aug;7(3):217-24 [doi: 10.1111/jicd.12152]. Epub 2015 May 15].
 51. Babbush CA, Kent JN, Misiak DJ. Titanium Plasma Spray (TPS) screw implants for the reconstruction of the edentulous mandible. *J Oral Maxillofacial Surg*; 44: 274-282, 1986.
 52. Cao ZL, Li X, Lin LJ, Chen YH. Immediate or delayed loading protocols for two-implant mandibular overdentures: A systematic review and meta-analysis of randomized controlled trials. *J Prosthet Dent*. 2021 Dec;126(6):742-748. doi: 10.1016/j.prosdent.2020.09.011. Epub 2020 Oct 31. PMID: 33139056.
 53. Tirone F, Genovesi F. Immediate implant placement and loading in the esthetic area when the buccal socket wall is significantly damaged. *J Esthet Restor Dent*. 2021 Jun;33(4):542-549. doi: 10.1111/jerd.12707. Epub 2021 Jan 7. PMID: 33410593.
 54. Zhao G, Zhou Y, Shi S, Liu X, Zhang S, Song Y. Long-term clinical outcomes of immediate loading versus non-immediate loading in single-implant restorations: a systematic review and meta-analysis. *Int J Oral Maxillofac Surg*. 2022 Apr 13:S0901-5027(22)00136-9. doi: 10.1016/j.ijom.2022.03.057. Epub ahead of print. PMID: 35430123.
 55. Becker, W.; Becker, B.E., Huffstetler, S. Early functional loading at 5 days for Brånemark implants placed into edentulous mandibles: a prospective, open-ended, longitudinal study. *J Periodontol*; 74(5): 695-702, 2003.
 56. Branemark, P.I., Breine, U., Adell, R., Hanson, B.O., Lindström, J., ÖHLSSON A. Intraosseous anchorage of dental prosthesis. I. Experimental studies. *Scandinavian Journal of plastic Reconstructive Surgery*; 3(2): 81-100, 1969.
 57. Branemark, P.I., Hansson, B.O., Adell, R., Breine, U., Lindström, J., Hallen, O., Öhman, H. Osseointegrated implants in the treatment of the edentulous jaws. Experience from a 10 years period. *Scandinavian Journal of Plastic Reconstructive Surgery*; 16: 1-132, 1977.
 58. Chiapasco, M., Gatti, C., Rossi, E., et al. Implant retained mandible overdentures with immediate loading. A retrospective multicenter study on 226 consecutive cases. *Clin Oral Implants Res*; 8: 48-57, 1997.
 59. Jiang X, Lin Y., Cui HY, Di P. Immediate loading of multiple splinted implants via complete digital workflow: A pilot clinical study with 1-year follow-up. *Clin Implant Dent Relat Res*. 2019 Apr 26 [doi: 10.1111/cid.12781].
 60. Kern, M., Att, W., Fritzer, E., Kappel, S., Luthardt, R.G., Mundt, T., Reissmann, D.R., Rädcl, M., Stiesch, M., Wolfart, S., Passia, N. Survival and Complications of Single Dental Implants in the Edentulous Mandible Following Immediate or Delayed Loading: A Randomized Controlled Clinical Trial. *J Dent Res*. 2018 Feb;97(2):163-170 [doi: 10.1177/0022034517736063]. Epub 2017 Oct 18].
 61. Liu, H., Liu, R., Wang, M., Yang, J. Immediate implant placement combined with maxillary sinus floor elevation utilizing the transalveolar approach and nonsubmerged healing for failing teeth in the maxillary molar area: A randomized controlled trial clinical study with one-year follow-up. *Clin Implant Dent Relat Res*. 2019 May 1 [doi: 10.1111/cid.12783].
 62. Misch, C.E., Wang, H.L., Misch, C.M. Rationale for the application of Immediate Load in Implant Dentistry: Part 1. *Implant Dentistry*; 13(3): 201-216, 2004a.
 63. Ohyama, H., Hamilton, A., Forman, M.S., Weber, H.P. Comparative observation of immediate and late placement of dental implants with immediate loading: A 14-year follow up case report. *J Oral Implantol*. 2019 Apr 22 [doi: 10.1563/aaid-joi-D-18-00290].
 64. Randow, K., Ericsson, I., Nilner, K., Petersson, A., Glantz, P.O. Immediate functional loading of Brånemark dental implants. An 18-month clinical follow-up study. *Clin Oral Implants Res*; 10(1): 8-15, 1999.
 65. Schnitman, P.A., Wohrle, O.S., Rubenstein, J.E. Immediate fixed interim prostheses supported by two-stage threaded implants: methodology and result *J Oral Implantol*, 16(2):96-105, 1990.
 66. Schnitman, P.A., Wohrle, P.S., Rubenstein, J.E., et al. Branemark implants immediately loaded with fixed prostheses at implant placement. Ten year results. *Int J Oral Maxillofac Implants*; 12:495-503, 1997.
 67. Schroeder, A., Van Der Zyper, E., STICH, H. et al. The reaction of bone, connective tissue and epithelium to endosteal implants with titanium-sprayed surfaces. *J Maxillofac. Surg*, 1: 15-25, 1981.
 68. spiekermann, H., Jansen, V.K., Richter, E.J. A 10-year follow-up study of IMZ and TPS implants in the edentulous mandible using bar-retained overdentures. *Int J Oral Maxillofac Implants*;

- 10(2): 231-43, 1995.
- 69.** Szmukler- Moncler, S., Salama, H., Reingewirtz, Y. et al. Timing of loadind of micromotion on bone-dental implants interface: review of experimental literature. J Biomed mater Res.; 43(2):192-203. 1998.
- 70.** Szmukler-Moncler, S., Piatelli, A., Favero, G.A. et al. Considerations preliminary to the application of early and immediate loading protocols in dental implantology. Clin Oral Impl Res.; 11(1): 12-25, 2000.
- 71.** Flanagan D, Fisher A, Ciardiello C, Moreno V, Pierce D, Uvalic A, Winsor J, Rubano M, Howard E, Lykotrafitis G. A Theoretical Iteration for Predicting the Feasibility for Immediate Functional Dental Implant Loading. J Oral Implantol. 2021 Aug 1;47(4):310-317. doi: 10.1563/aaid-joi-D-20-00194.
- 72.** Carvalho AM, Carvalho LP, Carvalho LF, Dias AL, Bezerra FJB, Bergamo ETP, Sotto-Maior BS. Rehabilitation of Atrophic Maxilla With Immediate Loading of Extrasinus Zygomatic Implant. J Craniofac Surg. 2021 Dec 13. doi: 10.1097/SCS.00000000000008411.
- 73.** Vogl, S., Stopper, M., Hof, M., Theisen, K., Wegscheider, W.A., Lorenzoni, M. Immediate occlusal vs nonocclusal loading of implants: A randomized prospective clinical pilot study and patient centered outcome after 36 months. Clin Implant Dent Relat Res. 2019 May 7 [doi: 10.1111/cid.12770].