



# Major clinical results of mentoplasty: a systematic review

Natália Roberta Martin<sup>1,2,4</sup>, Lucas Furtado<sup>1,2,3</sup>, Régis Manzini<sup>1,2\*</sup>

<sup>1</sup> UNORTE - University Center of Northern São Paulo - Dentistry department, Sao Jose do Rio Preto, Sao Paulo, Brazil.

<sup>2</sup> UNIPOS - Post graduate and continuing education, Dentistry department, Sao Jose do Rio Preto, Sao Paulo, Brazil.

<sup>3</sup> Dr. Lucas Furtado Clinic, Sao Jose do Rio Preto, Sao Paulo, Brazil.

<sup>4</sup> Ms Odontologia, Sao Jose do Rio Preto, Sao Paulo, Brazil.

\*Corresponding author: Prof. Régis Manzini,  
Unorte/Unipos - Post graduate and continuing  
education, Dentistry department, Sao Jose do Rio  
Preto, Sao Paulo, Brazil. E-mail: r01manzini@gmail.com  
DOI: <https://doi.org/10.54448/mdnt22S321>

Received: 02-14-2022; Revised: 04-27-2022; Accepted: 05-13-2022; Published: 06-01-2022; MedNEXT-id: e22S321

## Abstract

**Introduction:** In the context of oral and maxillofacial surgery, orthognathic surgery (OS) is used to improve the patient's facial appearance and to correct maxillary and mandibular deformities resulting from malocclusions, disease, or trauma. **Objective:** It was carried out a concise systematic review of the main clinical approaches to genioplasty (genioplasty), as well as the results of more current clinical studies, to show the state of the art of this surgery. **Methods:** The rules of the Systematic Review-PRISMA Platform were followed. The research was carried out from February 2022 to May 2022 and developed based on Scopus, PubMed, Science Direct, Scielo, and Google Scholar. The quality of the studies was based on the GRADE instrument and the risk of bias was analyzed according to the Cochrane instrument. **Results and Conclusion:** A total of 108 articles were found. In total, 68 articles were fully evaluated and 23 were included and evaluated in this study. And of the total of 23 articles, only 09 articles were developed as the main clinical results. A total of 16 articles were excluded because they did not meet the GRADE classification, and 45 were excluded because they were at risk of bias. Mentoplasty represents one of the most common auxiliary procedures and may be associated with corrective surgery for dentofacial dysmorphisms. However, care must be taken with mental nerve injuries, asymmetries, and intraoperative bleeding are the main immediate complications of mentoplasty, and to minimize these risks, the ultrasonic piezoelectric osteotomy with the selective cutting of the mineralized structure stands out. Furthermore, one-piece mentoplasty based on a three-dimensional impression model proved to be very successful for the natural modeling of the mandible.

Also, it has been shown that the use of piezotomes is advantageous in mentoplasty surgery compared to traditional surgical instruments. In the context of hylotherapy, the results of the study indicate slightly less residual edema at 18°C temperature on the 30th postoperative day. Finally, in orthognathic surgery, a fibrinolytic shutdown is significantly amplified by tranexamic acid.

**Keywords:** Oral and maxillofacial surgery. Mentoplasty. Genioplasty. Aesthetics. Clinical trials.

## Introduction

In the context of oral and maxillofacial surgery, orthognathic surgery (OS) is used to improve the patient's facial appearance and to correct maxillary and mandibular deformities resulting from malocclusions, disease or trauma [1-3]. The success of OS depends on the surgical technique and the precision of the orthodontic-surgical treatment plan [4,5]. In this sense, bilateral sagittal osteotomy of the ramus of the mandible is a technique widely used in orthognathic surgery for the correction of mandibular deformities [6-8]. Mandibular advancement is a procedure with a high risk of skeletal relapse, due to the difference between the proximal and distal bone segments [9].

Furthermore, non-ossification between the maxillary bones after osteotomies is an important complication [10]. Thus, several studies have already reported that areas of little or no bone contact in both the maxilla and the mandible may present a greater chance of instability. Furthermore, bone recovery would be inadequate if there was a defect greater than 3 mm between the segments along the osteosynthesis line [11].

In this aspect, in the cosmetic surgery scenario, in addition to the other parts of the face, the chin is one of the most important parts of the facial skeleton. The size and location of these areas of the skeleton in relation to the base of the skull and their three-dimensional positional relationship to each other are essential and contribute to the individuality of a human face. The position of the chin has a strong influence on the assessment of facial harmony, as its different types and shapes dominate the appearance. Also, the chin expression can signal character traits. In this context, genioplasty is a procedure to correct aesthetic and functional deformity of the chin region, improving the contour [12].

Also, authors demonstrated that the use of xenogenic bone graft in mandibular advancements greater than 8 mm performed clinical, radiographic and histological evaluations, and concluded that the material is an effective tool in bone stability and mandibular aesthetics, not causing an increase in postoperative complications [13]. In the maxilla in advances of up to 5 mm, promising results were also observed in bone union in Le Fort I osteotomies, requiring the need for studies with greater maxillary advances and in other areas, such as the chin in genioplasty [14].

Therefore, the present study carried out a concise systematic review on the main clinical approaches of mentoplasty (genioplasty), as well as the results of more current clinical studies, in order to show the state of the art of this surgery.

## Methods

### Study Design

The rules of the Systematic Review-PRISMA Platform (Transparent reporting of systematic reviews and meta-analysis-[HTTP://www.prisma-statement.org/](http://www.prisma-statement.org/)) were followed.

### Data sources and research strategy

The search strategies for this systematic review were based on the keywords (MeSH Terms): "Oral and maxillofacial surgery. Mentoplasty. Genioplasty. Aesthetics. Clinical trials". The research was carried out in February 2022 to May 2022 and developed based on Scopus, PubMed, Science Direct, Scielo, and Google Scholar. Also, a combination of the keywords with the booleans "OR", "AND", and the operator "NOT" were used to target the scientific articles of interest.

### Study Quality and Bias Risk

The quality of the studies was based on the GRADE instrument and the risk of bias was analyzed according

to the Cochrane instrument.

## Results and Discussion

A total of 108 articles were found. Initially, duplication of articles was excluded. After this process, the abstracts were evaluated and a new exclusion was performed, removing the articles that did not address the theme of this article. In total, 68 articles were fully evaluated and 23 were included and evaluated in this study (Figure 1). And of the total of 23 articles, only 09 articles were developed as the main clinical results. Of the initial total of articles, 16 articles were excluded because they did not meet the GRADE classification, and 45 were excluded because they presented a risk of bias that could compromise the credibility of the studies (Figure 1).

**Figure 1.** Study Eligibility (Systematic Review).

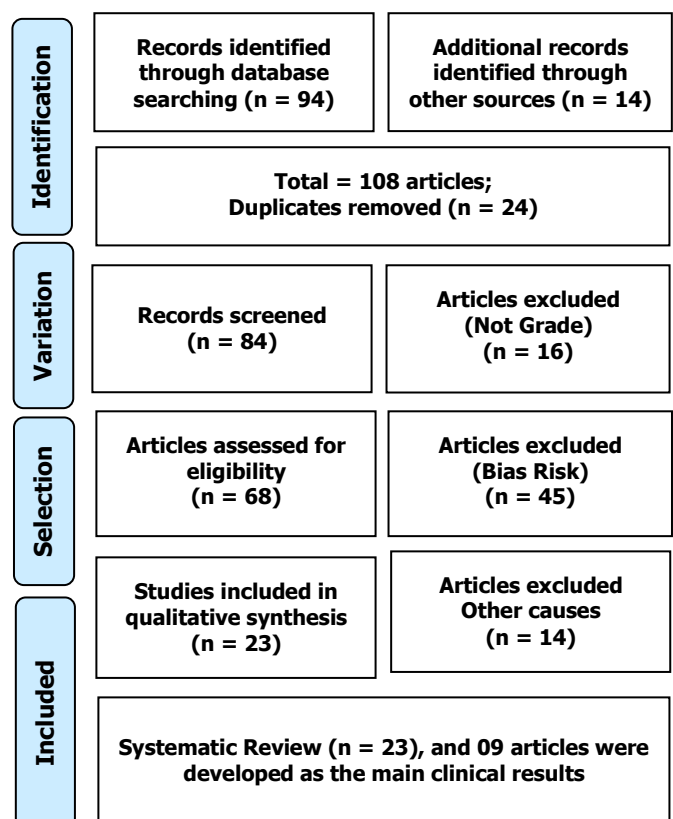
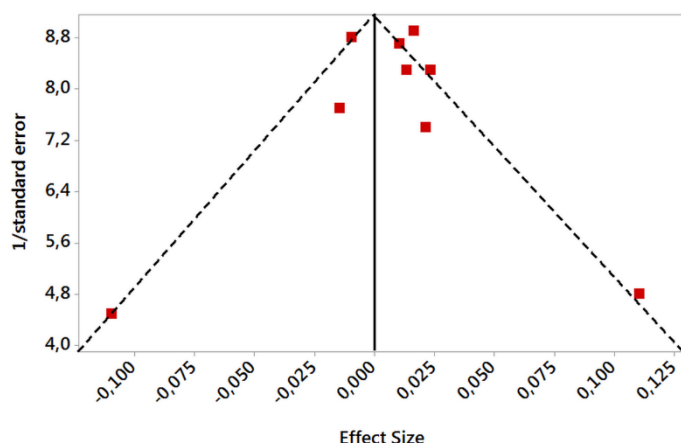


Figure 2 presents the results of the risk of bias in the studies using the Funnel Plot, through the calculation of the Effect Size (Cohen's Test). The sample size was determined indirectly by the inverse of the standard error. The number of clinical studies evaluated was n=09. The graph showed symmetric behavior, not suggesting a significant risk of bias in studies with small sample sizes, which are shown at the bottom of the graph.

**Figure 2.** The symmetric funnel plot does not suggest a risk of bias between the small sample size studies that are shown at the bottom of the graph. N=09 clinical studies.



### Major Clinical Results Of The Mentoplasty

Genioplasty (or mentoplasty) is a technique used for aesthetic and functional purposes, as well as mandibular implants [15]. There are different types of genioplasty [16]. Functional genioplasty is usually associated with orthognathic surgery, to achieve lip closure at rest, promoting nasal breathing and functional adult swallowing. They may also have stability benefits from orthodontic treatments and positive periodontal effects. Aesthetic genioplasty, on the other hand, is performed to correct excess or lack of projection of the chin, however, they must be monitored [16].

Thus, a study presented the application of the piezoelectric scalpel to correct different chin deformities. A total of 55 patients with a defective chin were included. Intraoral genioplasty was performed during the correction of dentofacial dysmorphisms or associated with nasal surgery. Piezosurgery has been associated with a lower number of postoperative complications, especially concerning intraoperative bleeding, nerve injuries (immediate and late), hematomas and seromas, and asymmetry (immediate and early). The average time to perform the complete mentoplasty procedure with piezosurgery was almost the same as the saw and drill. Therefore, genioplasty represents one of the most common auxiliary procedures and may be associated with corrective surgery for dentofacial dysmorphisms. However, care should be taken with mental nerve injuries, asymmetries, and intraoperative bleeding are the main immediate complications of mentoplasty, and to minimize these risks, the ultrasonic piezoelectric osteotomy with the selective cutting of the mineralized structure stands out [17].

Thus, in this respect, rhinoplasty and chin surgery

are effective procedures to resolve the defects of underdevelopment of the nose and chin. Thus, a study investigated application strategies of autologous costal cartilage grafts in rhinoplasty and mentoplasty. As a result, satisfactory facial contour appearance was achieved immediately in 28 patients after surgery. A total of 21 patients had a satisfactory appearance of the nose and chin during the 6 to 18-month follow-up. No cartilage resorption was observed. Two patients had redness of the skin of the nasal tip and were cured after treatment. Therefore, the application of autologous costal cartilage grafts has achieved satisfactory results [18].

Also, a randomized clinical trial compared the postoperative period of cooling (hylotherapy) temperatures of 18°C and 22°C. The parameters of this study were swelling and postoperative pain levels. A total of 156 patients were divided into two groups, in which mono-one, bignatic osteotomy, or mentoplasty was indicated. Postoperative assessment of swelling was performed using a 3D optical scanner. This examination was repeated on postoperative days 1, 2, 3, 7, 14, 30, and 90. Group 1 (18°C, 78 patients) had an increase in postoperative edema on the 1st postoperative day of  $52.06 \pm 35.41$  mL. The maximum was reached on the 2nd postoperative day with  $75.82 \pm 38.97$  mL. On the 30th postoperative day, residual swelling measured  $11.60 \pm 12.62$  mL. Group 2 (22 °C, 78 patients) had an increase in postoperative edema on the 1st postoperative day of  $76.07 \pm 63.15$  mL. The maximum was reached on the 2nd post-OP day with  $106.97 \pm 69.63$  mL. On the 30th postoperative day, residual swelling measured  $14.36 \pm 32.26$  mL. The differences between the two groups and between the different visits were statistically significant [19].

In this context of hylotherapy, it has not yet been clarified how the development of pain and swelling progresses postoperatively at different cooling temperatures. Thus, one study compared postoperative cooling temperatures of 18°C and 22°C. The parameters of this study were swelling and the postoperative development of pain levels. This study included 36 patients, divided into two groups, in which mono- or bignatic osteotomy or mentoplasty in orthognathic surgery was indicated, using a 3D optical scanner (FaceSCAN3D®) on days 1, 2, 3, 7, 14, 30, and 90 postoperative days. Group 1 (18 °C, 18 patients) had an increase in postoperative edema on the 1st postoperative day of  $62.22 \pm 36.29$  mL. The maximum was reached on the 3rd postoperative day with  $81.85 \pm 40.23$  mL. On the 30th postoperative day, residual edema measured  $7.39 \pm 15.77$  mL. Group 2 (22°C, 18 patients) had an increase in postoperative edema on the 1st postoperative day of  $61.69 \pm 34.7$  mL. The

maximum was reached on the 2nd postoperative day with  $92.83 \pm 48.03$  mL. On the 30th postoperative day, residual edema was  $28.09 \pm 19.04$  mL. Study results indicate slightly less residual edema in group 1 ( $18^{\circ}\text{C}$ ) on the 30th postoperative day [20].

Besides, a study performed mentoplasty in a single piece from the mandibular angle to the most anterior part of the chin to achieve the change of the entire mandibular shape like a single piece, with a total of 14 patients who complained of mandibular angle and chin. prominent. Group I ( $n=7$ ) was treated with conventional mentoplasty with narrowing rhinoplasty and Group II ( $n=7$ ) was treated with one-piece mentoplasty. The mean volume reduction per side was 41.8 cc in the one-piece mentoplasty and 36.5 ccs in the conventional mentoplasty with narrowing rhinoplasty. In addition, the lower facial mean decreased from 64.3 to 61.0 after 6 months postoperatively and was maintained up to 3 years on average after the operation. In the one-piece mentoplasty group, a little greater satisfaction was shown with the body of the mandible, and it was estimated that the presence of a secondary angle generates dissatisfaction. Therefore, one-piece mentoplasty based on a three-dimensional impression model proved to be very successful for the natural modeling of the mandible [21].

Furthermore, a randomized clinical trial wanted to confirm the clinical findings of recent studies that showed that piezotomes can establish the new "state of the art" for osteotomies in maxillofacial surgery. The sample consisted of 48 patients who underwent piezotome reduction chin surgery (10 men and 13 women; age, 24 to 56 years) or traditional sliding genioplasty (11 men and 14 women; age, 26 to 54 years). No statistically relevant differences were found for the duration of surgery between the test and control groups. There was a statistically significant association between decreased post-surgical morbidity and greater overall long-term patient satisfaction with the outcome of piezotome genioplasty. Therefore, the use of piezotomes is advantageous in rhinoplasty surgery compared to traditional surgical instruments [22].

Finally, a randomized clinical trial investigated the effects of OS on fibrin lysis, fibrin structure, and D-dimer and evaluated the effect of tranexamic acid on these fibrinolytic measures. Patients had a maxillary or mandibular deficiency, either excessive or asymmetrical. All patients underwent bimaxillary OS with or without maxillary segmentation or additional mentoplasty. The sample included 96 patients, of which 45 received placebo and 51 received tranexamic acid. As a result, it was observed that fibrin lysis decreased after OS. Fibrinolytic shutdown decreased significantly more in the tranexamic acid group than in the placebo group.

OS altered fibrin structure properties with comparable effects in the 2 groups. D-dimer increased postoperatively but was less significant in the tranexamic acid group than in the control group. Therefore, OS is associated with fibrinolytic shutdown and alters the properties of fibrin structure, driving hemostatic equilibrium in a prothrombotic direction. Fibrinolytic shutdown is significantly amplified by tranexamic acid [23].

## Conclusion

Mentoplasty represents one of the most common auxiliary procedures and may be associated with corrective surgery for dentofacial dysmorphisms. However, care must be taken with mental nerve injuries, asymmetries, and intraoperative bleeding are the main immediate complications of mentoplasty, and to minimize these risks, the ultrasonic piezoelectric osteotomy with the selective cutting of the mineralized structure stands out. Furthermore, one-piece mentoplasty based on a three-dimensional impression model proved to be very successful for the natural modeling of the mandible. Also, it has been shown that the use of piezotomes is advantageous in mentoplasty surgery compared to traditional surgical instruments. In the context of hylotherapy, the results of the study indicate slightly less residual edema at  $18^{\circ}\text{C}$  temperature on the 30th postoperative day. Finally, in orthognathic surgery, a fibrinolytic shutdown is significantly amplified by tranexamic acid.

## Acknowledgement

Not applicable.

## Funding

Not applicable.

## Ethics approval

Not applicable.

## Informed consent

Not applicable.

## Data sharing statement

No additional data are available.

## Conflict of interest

The authors declare no conflict of interest.

## Similarity check

It was applied by Ithenticate@.



## About the License

© The authors (s) 2022. The text of this article is open access and licensed under a Creative Commons Attribution 4.0 International License.

## References

1. Hirohi T. A New Concept of Narrowing Genioplasty: Home Plate-Shaped Sliding Osteotomy. *Plast Reconstr Surg.* 2021 Aug 1;148(2):309-319. doi: 10.1097/PRS.00000000000008187.
2. Alkhayer A, Piffkó J, Lippold C, Segatto E. Accuracy of virtual planning in orthognathic surgery: a systematic review. *Head Face Med.* 2020 Dec 4;16(1):34. doi: 10.1186/s13005-020-00250-2.
3. Ferri J, Schlund M, Touzet-Roumazielle S. Orthognathic Surgery in Craniosynostosis. *J Craniofac Surg.* 2021 Jan-Feb 01;32(1):141-148. doi: 10.1097/SCS.00000000000007154.
4. Cascino F, Aboh IV, Giovannoni ME, Pini N, Zerini F, Del Frate R, Carangelo BR, Xu J, Gabriele G, Gennaro P, Iannetti G. Orthognathic surgery: a randomized study comparing Piezosurgery and Saw techniques. *Ann Ital Chir.* 2021;92:299-304.
5. Cunha G, Oliveira MR, Salmen FS, Gabrielli MFR, Gabrielli MAC. How does bone thickness affect the split pattern of sagittal ramus osteotomy? *Int J Oral Maxillofac Surg.* 2020 Feb;49(2):218-223. doi: 10.1016/j.ijom.2019.05.011. Epub 2019 Jun 22.
6. Steenen SA, Becking AG. Bad splits in bilateral sagittal split osteotomy: systematic review of fracture patterns. *Int J Oral Maxillofac Surg.* 2016 Jul;45(7):887-97. doi: 10.1016/j.ijom.2016.02.001. Epub 2016 Feb 28.
7. Lin HH, Lonic D, Lo LJ. 3D printing in orthognathic surgery – A literature review. *Journal of the Formosan Medical Association*, v. 117, n. 7, p. 547–558, 2018.
8. Di Blasio C, Anghinoni ML, Di Blasio A. Virtual planning of a complex three-part bimaxillary osteotomy. *Case Reports in Dentistry*, 2017, n. 4.
9. Hernández-Alfaro F. et al. Three-Dimensional Analysis of Long-Term Stability After Bilateral Sagittal Split Ramus Osteotomy Fixed With a Single Miniplate With 4 Monocortical Screws and 1 Bicortical Screw: A Retrospective 2-Center Study. *Journal of Oral and Maxillofacial Surgery*, 2017, v. 75, n. 5, p. 1036–1045.
10. Friscia M. et al. Complications after orthognathic surgery: our experience on 423 cases. *Oral and Maxillofacial Surgery*, 2017, v. 21, n. 2, p. 171–177.
11. Kuvat SV. et al. Improving bony stability in maxillofacial surgery: use of osteogenetic materials in patients with profound ( $\geq 5$  mm) maxillary advancement, a clinical study. *Journal of Plastic, Reconstructive and Aesthetic Surgery*, 2009, v. 62, n. 5, p. 639–645.
12. Abadi M, Pour OB. Genioplasty. *Facial Plast Surg.* 2015 Oct;31(5):513-22. doi: 10.1055/s-0035-1567882.
13. Trevisiol L. et al. Grafting of large mandibular advancement with a collagen-coated bovine bone (bio-oss collagen) in orthognathic surgery. *Journal of Craniofacial Surgery*, 2012, v. 23, n. 5, p. 1343–1348.
14. Rohner D, Hailemariam S, Hammer B. Le fort i osteotomies using Bio-Oss® Collagen to promote bony union: A prospective clinical split-mouth study. *International Journal of Oral and Maxillofacial Surgery*, 2013, v. 42, n. 5, p. 585–591.
15. Shokri T, Rosi-Schumacher M, Petrauskas L, Chan D, Ducic Y. Genioplasty and Mandibular Implants. *Facial Plast Surg.* 2021 Dec;37(6):709-715. doi: 10.1055/s-0041-1735307.
16. Esnault O. Les reprises de génioplasties [Secondary genioplasty]. *Ann Chir Plast Esthet.* 2019 Nov;64(5-6):519-530. French. doi: 10.1016/j.anplas.2019.08.005. Epub 2019 Sep 9. PMID: 31515116.
17. Bertossi D, Albanese M, Nocini R, Mortellaro C, Kumar N, Nocini PF. Osteotomy in Genioplasty by Piezosurgery. *J Craniofac Surg.* 2021 May 1;32(3):e317-e321. doi: 10.1097/SCS.00000000000003150. PMID: 29944550.
18. Zhang L, Ma WS, Bai JP, Li XX, Li HD, Zhu T, Sun JY, Ge HG, Pang Y, Xue F, Cheng LY, Jin R, Zhang Y, Sun XM, Zhang YG. Comprehensive Application of Autologous Costal Cartilage Grafts in Rhino- and Mentoplasty. *J Craniofac Surg.* 2019 Oct;30(7):2174-2177. doi: 10.1097/SCS.00000000000005858. PMID: 31425405.
19. Bonitz L, El-Karmi A, Linssen J, Abel D, Hassfeld S, Bicsák Á. A randomized, prospective trial to assess the safety and efficacy of hilotherapy in patients after orthognathic surgery. *Oral Maxillofac Surg.* 2021 Dec;25(4):525-532. doi: 10.1007/s10006-021-00948-w. Epub 2021 Mar 5. PMID: 33674933; PMCID: PMC8571232.
20. El-Karmi A, Hassfeld S, Bonitz L. Development of swelling following orthognathic surgery at various cooling temperatures by means of hilotherapy-a

clinical, prospective, monocentric, single-blinded, randomised study. J Craniomaxillofac Surg. 2018 Sep;46(9):1401-1407. doi: 10.1016/j.jcms.2018.01.012. Epub 2018 Feb 2. PMID: 30031593.

21. Kim SC, Kwon JG, Jeong WS, Na D, Choi JW. One-Piece Mandibuloplasty Compared to Conventional Mandibuloplasty With Narrowing Genioplasty. J Craniofac Surg. 2018 Jul;29(5):1161-1168. doi: 10.1097/SCS.0000000000004458. PMID: 29521758.
22. Troedhan A. Piezotome Genioplasty Reduces Postsurgical Morbidity and Enhances Patient Satisfaction: A Randomized Clinical Trial. J Oral Maxillofac Surg. 2018 Jul;76(7):1564.e1-1564.e12. doi: 10.1016/j.joms.2018.02.015. Epub 2018 Feb 27. PMID: 29567435.
23. Sidelmann JJ, Gram JB, Godtfredsen ACM, Thorn JJ, Ingerslev J, Pinholt EM. Orthognathic Surgery-Induced Fibrinolytic Shutdown Is Amplified by Tranexamic Acid. J Oral Maxillofac Surg. 2020 Jul;78(7):1183-1189. doi: 10.1016/j.joms.2020.02.026. Epub 2020 Mar 3. PMID: 32224082.