



Investigation of the main clinical findings of maxillary sinus surgery with platelet-rich fibrin: a systematic review

Álvaro Augusto de Mello^{1,2*}, Edmilson da Silva Esteves^{1,2}, Régis Manzini^{1,2}

¹ UNORTE - University Center of Northern São Paulo - Dentistry department, Sao Jose do Rio Preto, Sao Paulo, Brazil.

² UNIPOS - Post graduate and continuing education, Dentistry department, Sao Jose do Rio Preto, Sao Paulo, Brazil.

*Corresponding author: Álvaro Augusto de Mello,
Unorte/Unipos - Post graduate and continuing
education, Dentistry department, Sao Jose do Rio
Preto, Sao Paulo, Brazil.

E-mail: alvarus51@hotmail.com

DOI: <https://doi.org/10.54448/mdnt22S316>

Received: 02-06-2022; Revised: 04-24-2022; Accepted: 04-25-2022; Published: 05-11-2022; MedNEXT-id: e22S316

Abstract

Introduction: The maxillary sinus is the largest of the paranasal sinuses and its function is to contribute to phonation resonance, conditioning the air we breathe and aiding in the production of mucus in the nasal cavity. Around 25% of all maxillary sinuses, there is an accessory bone that is located in a lower portion than the main ostium. Aiming to increase the bone formation potential of these grafts, combinations have been proposed to obtain better regenerative conditions through volume preservation and induction of cell migration differentiation. **Objective:** Conducted a systematic review of the main clinical findings of maxillary sinus surgery using Platelet-rich fibrin. **Methods:** The present study followed a systematic review model (PRISMA). Experimental and clinical studies were selected, involving retrospective, prospective and randomized studies. The online databases consulted were PubMed, Scopus, Ovid, Periodicos.com, and Google Scholar. **Results and Conclusion:** A total of 59 articles were found involving the surgery of the maxillary sinuses using plasma rich in fibrin. A total of 34 articles were fully evaluated and 24 were included and discussed in this study. Studies have shown that PRF has the characteristic of polymerizing. The incorporation of circulating cytokines increases in the fibrin network, implying a longer life for these cytokines, as they will be released and used only in the remodeling of the initial scar matrix, which is long-term. PRF is based on protecting growth factors from proteolysis that can maintain their activity for a longer period and stimulate bone regeneration more efficiently. Another study indicated the use of fibrin membranes obtained from PRF to seal the perforations. In the

presence of perforations larger than 10.0 mm, the surgery must be aborted and re-entry performed after 60 to 90 days. Furthermore, the combination of biomaterial and PRF significantly improved bone regeneration in the peri-implant area. Therefore, although the results do not seem to confirm that PRF is better than other biomaterials, it is suggested that its use can result in a decrease in the total healing time, around 104 days, and improve the handling of the graft material.

Keywords: Maxillary sinus. Maxillary sinus surgery. Maxillary sinus augmentation. Platelet-rich fibrin. Biomaterials.

Introduction

In the context of maxillary facial surgery, the maxillary sinus is the largest of the paranasal sinuses and its function is to contribute to phonation resonance, conditioning the air we breathe and aiding in the production of mucus in the nasal cavity [1,2]. It also acts to equalize barometric pressures in the nasal cavity, which is covered by a membrane called Schneider's membrane. This membrane is made up of a cylindrical pseudostratified epithelium with calciform cells that produce mucus. The importance of knowing the constitution of this epithelium is since these hair cells play a fundamental role in the physiology of the maxillary sinus. While the calciform cells produce mucus, these cilia generate movements that cause this mucus to be directed to the drainage site of the maxillary sinus [2,3].

In this context, the maxillary sinus drains through its ostium in the nasal cavity, which usually occurs in the middle meatus. Around 25% of all maxillary sinuses,

there is an accessory bone that is located in a lower portion than the main ostium, and all the mucus produced and the particles trapped in this mucus are directed through the ciliary beat to the ostium [4]. When a dental element is lost in the posterior region of the maxilla, there is natural reabsorption of the alveolar process and, at the same time, pneumatization of the maxillary sinus will occur. It will increase its volume towards the location where the roots existed and this will often make it difficult or impossible to restore implants at the location [5]. For this reason, the maxillary sinus floor elevation procedure should be performed, or short implants when possible. When grafting procedures are needed, our focus is often on the type of biomaterial to be used and the success and predictability of our results do not depend only on the biomaterial.

In this aspect, it is also necessary to consider the type of defect to be treated, its morphology. The morphology will impact mainly because the defects have different vascularization capacities, different osteogenic cell recruitment capacities, different graft natural stabilization capacities, therefore, we must consider the characteristics of the biomaterials that we must employ, but also the characteristics of the bed and the bone defect that we intend to treat [6].

In addition, several surgical techniques can be used to reconstruct the atrophic alveolar ridge, isolated techniques, or associated with autogenous, allogeneic, xenogeneic, and alloplastic biomaterials. The autogenous bone graft is the only one capable of presenting three important biological properties (osteogenesis, osteoinduction, and osteoconduction) guaranteeing a self-regenerative potential [2]. As a disadvantage to autogenous bone graft, the need for second surgical access in the donor area is highlighted, resulting in longer surgical time, morbidity, and a consequent greater resistance of the patient to the proposed treatment [2].

In this sense, allogeneic, xenogenous, and alloplastic bone grafts are an alternative for the treatment of bone deficiencies in the jaws, as they avoid the need for a second surgical approach. But due to the need for processing to eliminate antigenic components, these grafts are uniquely osteoconductive with a lower bone formation potential compared to the autogenous bone graft [7]. Aiming to increase the bone formation potential of these grafts, combinations have been proposed to obtain better regenerative conditions through volume preservation and induction of cell migration differentiation.

Also, in the last 20 years, platelet concentrates have been proposed as regenerative materials in tissue

regeneration procedures. Among the platelet concentrates proposed in the literature, there are PRP and PRF that act as autogenous platelet aggregates with osteoinductive properties. These biomaterials, due to their low morbidity and possible regenerative potential, have been indicated for use in combination with other biomaterials or even alone [2].

Therefore, the present study performed a systematic review of the main clinical findings of maxillary sinus surgery using Platelet-rich fibrin.

Methods

Study Design and Strategy Search

The present study follows a systematic review model, following the rules of systematic review - PRISMA (Transparent reporting of systematic review and meta-analysis, access available in: <http://www.prisma-statement.org/>). Experimental and clinical studies were selected, involving retrospective, prospective and randomized studies. Initially, keywords were determined by searching the DeCS tool (Descriptors in Health Sciences, BIREME base) and then verified and validated by the MeSH System (Medical Subject Headings, the US National Library of Medicine) to achieve a consistent search.

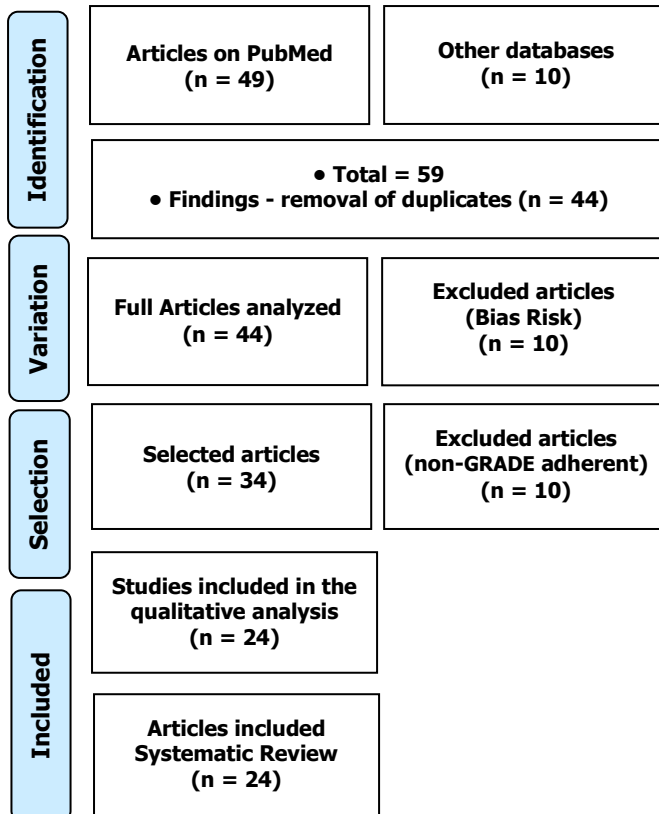
The main descriptors (Mesh Terms) used were "*Maxillary sinus. Maxillary sinus surgery. Maxillary sinus augmentation. Platelet-rich fibrin. Biomaterials*". For further specification, the "Maxillary sinus augmentation" description for refinement was added during searches. The bibliographic search was carried out through online databases: PubMed, Scopus, Ovid, Periodicos.com, and Google Scholar.

Results and Discussion

A total of 59 articles were found involving the surgery of the maxillary sinuses using plasma rich in fibrin. Initially, the existing title and duplications were excluded according to the interest described in this work. After this process, the abstracts were evaluated and a new exclusion was performed. A total of 34 articles were fully evaluated and 24 were included and discussed in this study (Figure 1).

In the scenario of maxillary sinus surgery, the lack of bone in the alveolar crests has been a major problem in functional esthetic recovery in patients who have suffered dentoalveolar trauma, traumatic tooth extractions, congenital tooth loss, maxillary and mandibular pathologies, in addition to infections due to the emotional and the possibility of deformity and also the economic impact they cause on the National Health System (NHS) [3,4].

Figure 1. Article selection process.



Furthermore, bone loss can also occur due to periodontal disease, traumatic surgery, or even for physiological reasons due to lack of adequate or inadequate prosthetic load [1,5]. Trauma in the face region can affect both soft tissue and hard tissue, so these injuries can affect the quality of life and health of the victim [2,5].

Maxillofacial trauma can be considered one of the most devastating aggressions found in traumatology and oncology due to the emotional consequences and the possibility of deformity, as well as the economic impact they cause on the Unified Health System (NHS) [6]. The face, more than any other region of the body, is affected by aesthetic changes as it is always visible and damage is immediately noticed. For this reason, facial trauma deserves attention in the treatment of multiple trauma due to its high incidence and severity [1].

In this context, Platelet-rich fibrin (PRF) as an autologous biomaterial was developed in France by Choukroun et al. (1993) [6] for specific use in oral and maxillofacial surgery. This biomaterial has the majority of leukocytes, platelets, and growth factors, forming a fibrin matrix, with a three-dimensional architecture. It is the second generation of platelet concentrate with a high potential for wound repair.

Furthermore, obtaining PRF follows an easy and simple protocol. A blood sample is obtained without anticoagulant in 10.0 mL tubes that are immediately

centrifuged at 3000 rpm (approximately 400.0 g) for 10.0 minutes [5]. After starting centrifugation in the absence of anticoagulant, the activation of most of the collected blood platelets starts, from the contact with the tube walls and the release of the coagulation cascades. As a final product of this process, we have fibrinogen, which is a soluble protein, transformed into insoluble fibrin by thrombin. Fibrin gel constitutes the first scar matrix of injured sites. Fibrinogen is concentrated at the top of the tube, before circulating thrombin converts it to fibrin. A fibrin clot is then obtained in the middle of the tube, between the red blood cells at the bottom and the acellular plasma at the top [8,9].

Besides, PRF has the characteristic of polymerizing naturally and slowly during centrifugation. The fibrin network thus formed presents, in particular, a homogeneous three-dimensional organization, more coherent than the natural fibrin clots [10-12]. In this context, with progressive polymerization, the incorporation of circulating cytokines increases in the fibrin network, implying a longer life for these cytokines, as they will be released and used only in the remodeling of the initial scar matrix, which is long-term [13,14]. Cytokines are thus kept available in situ for a convenient period when cells begin matrix remodeling [15].

Furthermore, PRF is based on protecting growth factors from proteolysis that can maintain their activity for a longer period and stimulate bone regeneration more efficiently [16]. The most critical phase of the sinus membrane elevation procedure after maxillary sinus lateral wall osteotomy is its detachment [17]. At this stage, ruptures of Schneider's membrane may occur, in around 15.0% of the cases, which, depending on the size of the perforation, may make the graft unfeasible, mainly due to the containment character of the graft material that the membrane exerts. The most frequent causes of these perforations are inadequate osteotomies, incomplete membrane detachments with lack of bone support for lifting cures, exerting excessive pressure on the membrane, and presence of septa [17-21].

Furthermore, if sinus membrane perforations are present, this must be quantified [22], as small perforations do not require treatment as membrane folds obliterate the perforation. In the case of ruptures greater than 5.0 mm, the use of collagen membranes is indicated [23]. Another study indicated the use of fibrin membranes obtained from PRF to seal the perforations. In the presence of perforations larger than 10.0 mm, the surgery must be aborted and re-entry performed after 60 to 90 days [24].

In this sense, the development of optimized implant surfaces is a matter of great research to

accelerate the osseointegration process, leading to a reduction in the waiting time before loading, in addition to making immediate implant loading safer [1]. It was documented for the first time that the combination of biomaterial and PRF significantly improved bone regeneration in the peri-implant area. The placement of the implant with the simultaneous use of the PRP creates a good relationship between the hard tissue and the soft tissue, in addition to the advantage of the psychological relationship with the patient [2].

In this aspect, cell migration and proliferation on the implant surface are essential to initiate the tissue regeneration process, while modifications on the implant surface incorporating growth and differentiation mediators can enhance tissue regeneration for the implant [4-7]. Xenografts are bone minerals derived from animals or algae and corals. The organic component is removed to eliminate the risk of immunogenic responses or disease transmission. Animal derivatives are the most used in guided bone regeneration, especially deproteinized sterilized bovine medullary bone, which has been extensively researched and shown to have similarities with human medullary bone. Deproteinized sterilized bovine medullary bone is an excellent osteoconduction, providing a favorable framework for bone formation. Its slow resorption contributes a lot to maintaining the graft volume. It has good wettability and a good surface contact angle, favoring contact with the blood clot. Elevations of the floor of the maxillary sinus performed using exclusively deproteinized sterilized bovine medullary bone demonstrate good osteoconductive capacity and excellent biological integration, which facilitates bone neoformation. A study with deproteinized sterilized bovine medullary bone used alone or mixed with autogenous bone at different percentages in maxillary sinus floor elevation demonstrated bone formation similar to that of autogenous bone after 9 months [18].

Still, the most used xenograft in guided bone regeneration procedures is the deproteinized bovine bone mineral, commercially known as Bio-Oss®, it is the most researched product in regenerative dentistry worldwide. It is a bone of bovine origin processed to produce natural bone minerals without organic elements. After thermal and chemical treatments, the inorganic phase of bovine bone consists mainly of hydroxyapatite (HA) which retains the porous architecture. The excellent osteoconductive properties of Bio-Oss® lead to predictable and efficient bone regeneration, Bio-Oss® particles become an integral part of the newly formed bone structure and conserve their volume in the long term [21]. Due to its 'great' resemblance to the human bone, the Bio Oss® is 'incorporated' into the 'natural' process of 'shaping' and

'reshaping'. The highly porous structure of the Bio Oss® offers plenty of room for the formation of blood vessels (angiogenesis) and the deposit of neoformed bone. The 'microstructure' of the 'surface' of Bio Oss® supports the 'excellent growth' of osteoblasts, which are 'responsible' for 'bone formation [21].

Therefore, although the results do not seem to confirm that PRF is better than other biomaterials, it is suggested that its use can result in a decrease in the total healing time, around 104 days, and improve the handling of the graft material. In addition, the use of PRF associated with Bio-Oss® seems to illustrate high success rates with minimal costs, which can reduce the amount of bone graft needed to fill the sinus cavity, reducing procedure costs [22].

Conclusion

Although the results do not seem to confirm that PRF is better than other biomaterials, it is suggested that its use can result in a decrease in the total healing time, around 104 days, and improve the handling of the graft material.

Acknowledgement

Not applicable.

Funding

Not applicable.

Data sharing statement

No additional data are available.

Conflict of interest

The authors declare no conflict of interest.

Similarity check

It was applied by Ithenticate@.

About the License

© The authors (s) 2022. The text of this article is open access and licensed under a Creative Commons Attribution 4.0 International License.

References

1. Wang J, Sun X, Lv H, Du L, Wang L, Zhou Y. Endoscope-Assisted Maxillary Sinus Floor Elevation with Platelet-Rich Fibrin Grafting and Simultaneous Implant Placement: A Prospective Clinical Trial. *Int J Oral Maxillofac Implants*. 2021 Jan-Feb;36(1):137-145. doi: 10.11607/jomi.8723. PMID: 33600535.

2. Irdem HO, Dolanmaz D, Esen A, Ünlükal N, Şimsek S. Evaluation of the Effectiveness of Liquid Platelet-Rich Fibrin and Deproteinized Bovine Bone Mineral Mixture on Newly Formed Bone in Maxillary Sinus Augmentation: A Split-Mouth, Histomorphometric Study. *Niger J Clin Pract.* 2021 Sep;24(9):1366-1372. doi: 10.4103/njcp.njcp_692_20. PMID: 34531351.
3. Abdel-Kader MA, Abdelazeem AF, Ahmed NEB, Khalil YM, Mostafa MI. Oral rehabilitation of a case with regional odontodysplasia using a regenerative approach-A case report and a review of literature. *Spec Care Dentist.* 2019, May;39(3):330-339. doi: 10.1111/scd.12378. Epub 2019 Apr 16.
4. Arab H, Shiezadeh F, Moeintaghavi A, Anbiaei N, Mohamadi S. Comparison of Two Regenerative Surgical Treatments for Peri-Implantitis Defect using Natix Alone or in Combination with Bio-Oss and Collagen Membrane. *J Long Term Eff Med Implants.* 2016;26(3):199-204. doi: 10.1615/JLongTermEffMedImplants.2016016396.
5. Chiapasco M, Casentini P, Zaniboni M. Bone augmentation procedures in implant dentistry. *Int J Oral Maxillofac Implants.* 2009;24 Suppl: 237-59.
6. Choukroun J, Diss A., Simonpieri A, Girard MO, Schhoffer C, Dohan SL, et al. Platelet-rich-fibrin (PRF): a second generation platelet concentrate. Part IV: clinical effects on tissue healing. *Oral Surg. Oral Med. Oral Pathol. Oral Radiol. Endod* 2006; 101 (3): e 56 – 60.
7. Diana C, Mohanty S, Chaudhary Z, Kumari S, Dabas J, Bodh R. Does platelet-rich fibrin have a role in osseointegration of immediate implants? A randomized, single-blind, controlled clinical trial. *Int J Oral Maxillofac Surg.* 2018 Sep;47(9):1178-1188. doi: 10.1016/j.ijom.2018.01.001. Epub 2018 May 7.
8. Dohan DM, Choukroun J, Diss A, Dohan SL, Dohan AJJ, Mouhyi J, et al. Platelet-rich-fibrin (PRF); A second generation concentrate. Part I: Technological concepts and evolution. *Oral Surgery, Oral Medicine, Oral Pathology, Oral Radiology and Endodontology.* 2006; 101 (3): e 37- e 44.
9. Jeong SM, Lee CU, Son JS, Oh JH, Fang Y, Choi BH. Simultaneous sinus lift and implantation using platelet-rich-fibrin as sole grafting material. *J. Craniomaxillofac Surgery.* 2014; 42 (6): 990 – 4.
10. Li P, Zhu H, Huang D. Autogenous DDM versus Bio-Oss granules in GBR for immediate implantation in periodontal postextraction sites: A prospective clinical study. *Clin Implant Dent Relat Res.* 2018 Dec;20(6):923-928. doi: 10.1111/cid.12667. Epub 2018 Sep 19.
11. Momen-Heravi F, Peters SM, Garfinkle L, Kang P. Acellular Dermal Matrix as a Barrier for Guided Bone Regeneration of Dehiscence Defects Around Dental Implants: A Clinical and Histological Report. *Implant Dent.* 2018 Aug;27(4):521-524 [doi: 10.1097/ID.0000000000000796].
12. Moreira, A.C., Silva, J.R., Samico, R.P., Nishioka, G.N.M., Nishioka, R.S. Application of Bio-Oss in tissue regenerative treatment prior to implant installation: literature review. *Braz Dent Sci.* 22(2), 2019.
13. Nicoli, L. G., Pigossi, S. C., Araújo, R.F. d S.B., Marcantonio, C., Marcantonio, E., Marcantonio, JR. E. Multidisciplinary approach to oral rehabilitation with dental implants after gunshot injury. *The Journal of Prosthodontic Dentistry.* 2018; 119 (3): 329 – 33.
14. Nizam N, Eren G, Akcali A, Donos N. Maxillary sinus augmentation with leukocyte and platelet-rich fibrin and deproteinized bovine bone mineral: A split-mouth histological and histomorphometric study. *Clin Oral Implants Res.* 2018 Jan;29(1):67-75 [doi: 10.1111/clr.13044. Epub 2017 Aug 8].
15. Pichotano EC, De Molon RS, Freitas De Paula LG, De Souza RV, Marcantonio EJR, Zandim-BArceles DL. Early Placement of Dental Implants in Maxillary Sinus Grafted With Leukocyte and Platelet-Rich Fibrin and Deproteinized Bovine Bone Mineral. *J Oral Implantol.* 2018 Jun;44(3):199-206. doi: 10.1563/aaid-joi-D-17-00220. Epub 2018 Feb 19.
16. Starch-Jensen T, Aludden H, Hallman M, Dahlin C, Christensen AE, Mordenfeld AA. Systematic review and meta-analysis of long-term studies (five or more years) assessing maxillary sinus floor augmentation. *Int J Oral Maxillofac Surg.* 2018 Jan;47(1):103-116. doi: 10.1016/j.ijom.2017.05.001. Epub 2017 May 22.
17. Strauss FJ, Stähli A, Gruber R. The use of platelet-rich fibrin to enhance the outcomes of implant therapy: A systematic review. *Clin Oral Implants Res.* 2018 Oct;29 Suppl 18:6-19. doi: 10.1111/clr.13275.
18. Tajima N, Ohba S, Sawase T, Asahima I. Evaluation of sinus floor augmentation with simultaneous implant placement using platelet-rich-fibrin as sole grafting material. *Int J Oral Maxillofac Implants* 2013;28(1):77- 83.

19. Tatullo M, Marrelli M, Cassetta M, Pacifici A, Stefanelli LV, Scacco S, Dipalma G, Pacifici L, INchingolo F. Platelet Rich Fibrin (PRF.) in reconstructive surgery of atrophied maxillary bones: clinical and histological evaluations. *Int J Med Sci.* 2012;9(10):872-80 [doi: 10.7150/ijms.5119. Epub 2012 Nov 7].
20. Wu IH, Bakhshalian N, Galaustian R, Naini RB, Min S, Freire M, Zadeh HH. Retrospective Analysis of the Outcome of Ridge Preservation with Anorganic Bovine Bone Mineral: Marginal Bone Level at Implants Placed Following Healing of Grafted Extraction Sockets. *Int J Periodontics Restorative Dent.* 2019 Jan/Feb;39(1):131-140. doi: 10.11607/prd.3308.
21. Xuan F, Lee CU, Son JS, Jeong SM, Choi BH. A comparative study of the regenerative effect of sinus bone grafting with platelet-rich fibrin-mixed Bio-Oss® and commercial fibrin-mixed Bio-Oss®: an experimental study. *J Craniomaxillofac Surg.* 2014 Jun;42(4):e47-50 [doi: 10.1016/j.jcms.2013.05.029. Epub 2013 Aug 2].
22. You JS, Kim SG, Oh JS, Kim JS. Effects of Platelet-Derived Material (Platelet-Rich Fibrin) on Bone Regeneration. *Implant Dent.* 2019 Mar 8 [doi: 10.1097/ID.0000000000000877].
23. Zhang Y, Tangl S, Huber CD, Lin Y, Qiu L, Raush-Fan X. Effects of Choukroun's platelet-rich-fibrin on bone regeneration in combination with deproteinized bovine bone mineral in maxillary sinus augmentation: a histological and histomorphometric study. *J Craniomaxillofac Surg.* 2012; 40 (4): 321 -8.
24. Zhou J, Li X, Sun X, Qi M, Chi M, Yin L, Zhou Y. Bone regeneration around immediate placed implant of molar teeth with autologous platelet-rich fibrin: Two case reports. *Medicine (Baltimore).* 2018 Nov;97(44):e13058. doi: 10.1097/MD.00000000000013058.