



# Major clinical results of the application of icon® in dental enamel hypoplasia: a systematic review

Thaísa Pecini Pinelli<sup>1,2</sup>, Nathalia Pecini Pinelli<sup>1,2</sup>, Beatriz Mansur Tertuliano<sup>1,2</sup>, Taylane Soffener Berlanga de Araújo<sup>1,2\*</sup>

<sup>1</sup> UNORTE - University Center of Northern São Paulo - Dentistry department, Sao Jose do Rio Preto, Sao Paulo, Brazil.

<sup>2</sup> UNIPOS - Post graduate and continuing education, Dentistry department, Sao Jose do Rio Preto, Sao Paulo, Brazil.

\*Corresponding author: Dr. Taylane Soffener Berlanga de Araújo. Unorte/Unipos – Graduate and Postgraduate in dentistry, Sao Jose do Rio Preto, Sao Paulo, Brazil.

E-mail: [taylane@terra.com.br](mailto:taylane@terra.com.br)

DOI: <https://doi.org/10.54448/mdnt22S314>

Received: 02-09-2022; Revised: 04-24-2022; Accepted: 04-29-2022; Published: 05-11-2022; MedNEXT-id: e22S314

## Abstract

**Introduction:** In the scenario of dental enamel hypoplasia, Molar Incisor hypomineralization (MIH) represents qualitative enamel developmental defects. The prevalence of MIH is approximately 13% worldwide. In addition, children affected by MIH undergo dental treatment on their first permanent molars nearly ten times as often as children without MIH. **Objective:** It was to carry out a systematic review of clinical studies on the use of ICON® in dental enamel hypoplasia, to discuss the advantages of this resin in patients. **Methods:** The present study followed a systematic review model, following the rules of systematic review – PRISMA. The search strategy was performed in the PubMed, Cochrane Library, Web of Science and Scopus, and Google Scholar databases. The quality of the studies was based on the GRADE instrument and the risk of bias was analyzed according to the Cochrane instrument. **Results and Conclusion:** A total of 122 articles were found. A total of 46 articles were fully evaluated and 25 were included in this study. Based on recent findings in the literature, the aesthetic results of ICON® infiltration proved to be effective, both in visual qualitative and quantitative spectrophotometric assessment. Furthermore, the infiltration of ICON® positively influenced the maintenance of the structural integrity of teeth affected by MIH, reducing the risk of enamel breakage. It also proved to be a minimally invasive treatment for tooth discoloration, less aggressive than conventional procedures. In addition to masking enamel white spot lesions, resin infiltration can involve residual enamel crystallites forming a hybrid enamel layer. Regarding the highest penetration and the highest percentages of penetration area, ICON® proved to be

better than other resins such as Biscover LV (Bisco), Optiguard (Kerr Hawe), and Permaseal (Ultradent).

**Keywords:** Hypomineralization. Enamel hypoplasia. Resin infiltration. ICON®. Aesthetics.

## Introduction

In the scenario of dental enamel hypoplasia, Molar Incisor hypomineralization (MIH) represents qualitative enamel developmental defects [1]. The prevalence of MIH is approximately 13% worldwide [2]. Furthermore, children affected by MIH undergo dental treatment on their first permanent molars almost ten times more often than children without MIH [3].

Furthermore, hypo mineralized lesions vary in color from cream/white to yellow and brown [4]. Thus, enamel has decreased mechanical properties due to the disorganized prismatic structure with lower mineral density and higher protein content, leading to increased porosity [5]. It is more common for the affected enamel to develop post-eruptive enamel degradation, facilitating the accumulation of plaque and the development of carious lesions [6]. In this regard, fluoride-based materials are commonly used in clinical practice to support lesion surface remineralization and further reduce demineralization. However, about 20% of yellow and brown MIH defects still develop even after fluoride varnish therapy [7,8].

In an attempt to improve the physical characteristics of lesions in MIH, infiltration with low-viscosity resin material has been investigated [9-11]. Thus, resin infiltration (RI) therapy is based on the penetration of a low-viscosity TEGDMA-based resin into the body of the lesion by capillary forces, promoting the

obliteration of porosities and preventing the progression of the lesion [12,13]. Considering this mechanism of action, RI has been proposed for the treatment of enamel developmental defects [9-11].

In this sense, hypomineralization is a challenge, and patients with more frequent esthetic concerns require tissue preservation and minimally invasive treatments of tooth color abnormalities. Until recently, fluoride or casein phosphopeptide treatments were used [14,15]. However, outcomes are often hampered by a lack of patient compliance, which can be a particular concern with adolescents. Furthermore, the aesthetic effect is generally not satisfactory [16]. To overcome these limitations, a new minimally invasive treatment using resin infiltration was recently proposed, ICON®, a product developed for the first time to stop caries in the posterior segment [17].

As evidence of this, an in vitro research study compared the masking ability and penetration ability of three composite resin types of cement as well as a resin infiltrant in shallow artificial caries lesions. The samples were randomly assigned to 5 groups: ICON® (DMG America), Biscover LV (Bisco), Optiguard (Kerr Hawe), Permaseal (Ultradent), and control (no treatment). ICON®, Optiguard, and Permaseal produced significantly higher visual analog scale scores compared to Biscover. Mean penetration area and depth were significantly higher for ICON®, intermediate for Optibond and Permaseal, and significantly lower for Biscover. Therefore, ICON® resulted in the highest penetration and the highest percentages of penetration area [18].

Therefore, the present study aimed to carry out a systematic review of clinical studies on the use of ICON® in dental enamel hypoplasia, to discuss the advantages of this resin in patients.

## Methods

### Study Design

The present study followed a systematic review model, following the rules of systematic review - PRISMA (Transparent reporting of systematic review and meta-analysis, access available in: <http://www.prisma-statement.org/>).

### Data Sources

The search strategy was performed in the PubMed, Cochrane Library, Web of Science and Scopus, and Google Scholar databases. The present study was carried out from January to March 2022.

## Descriptors (MeSH Terms)

The main descriptors (MeSH Terms) used were “Hypomineralization. Enamel hypoplasia. Resin infiltration. ICON®. Aesthetics”. For greater specification, the description “ICON® and Dental Aesthetics” for refinement was added during the searches, following the rules of the word PICOS (Patient; Intervention; Control; Outcomes; Study Design).

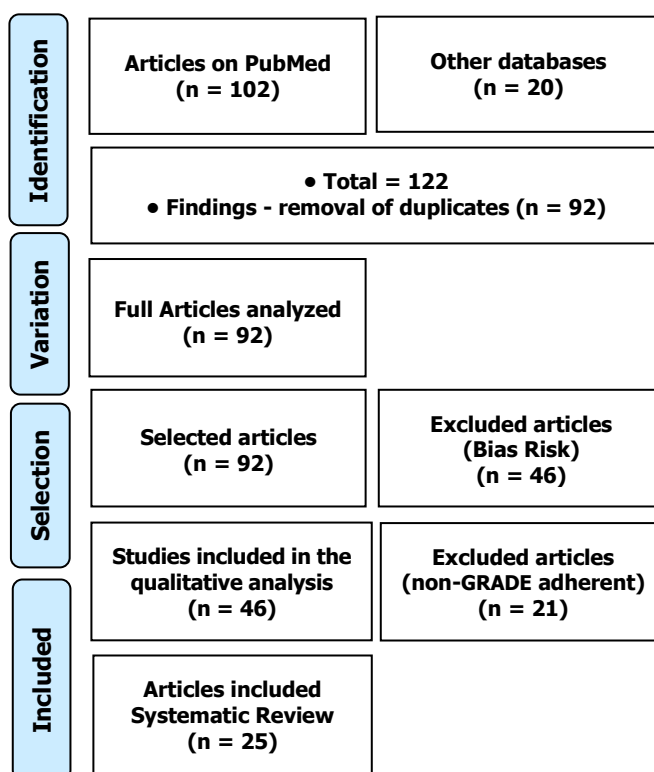
## Selection of studies and risk of bias in each study

Two independent reviewers (1 and 2) performed research and study selection. Data extraction was performed by reviewer 1 and fully reviewed by reviewer 2. A third investigator decided some conflicting points and made the final decision to choose the articles. The quality of the studies was based on the GRADE instrument and the risk of bias was analyzed according to the Cochrane instrument.

## Results and Discussion

A total of 122 articles were found. Articles that presented low-quality scientific evidence according to GRADE, as well as articles that showed research biases, such as a low number of participants and dubious results were also excluded. A total of 46 articles were fully evaluated and 25 were included in this study (Figure 1).

**Figure 1.** Article selection (Systematic Review).



After analyzing the literary findings, a study created an evaluation method to qualitatively and quantitatively evaluate the clinical outcome of enamel hypomineralization treatment with infiltrative resin in young adolescents. A total of 76 teeth from patients from Sapienza University (Rome, Italy) with early carious lesions and/or enamel development defect on the labial surface of the crown underwent resin infiltration. Mean scaling and color difference scores were evaluated before and after treatment and were found to be large across the entire sample. A clear correlation was detected between the visual inspections and the spectrophotometric color difference of the clinical results. Therefore, the aesthetic result of resin infiltration proved to be effective, both in the visual qualitative assessment and in the spectrophotometric quantitative assessment [19].

Furthermore, an 18-month randomized clinical trial evaluated the influence of fluoride varnish (FV) or resin infiltration (RI) therapies to maintain the structural integrity of teeth affected by MIH. Fifty-one children aged 6 to 12 years with at least one incisor and one permanent first molar with yellow/brown MIH opacities were included. Out of a total of 235 teeth, the rate for RI (6.1%) was significantly lower ( $p < 0.05$ ) than FV (17.9%; OR 3.0, 95% CI). Resin positively influenced the maintenance of the structural integrity of teeth affected by MIH, decreasing the risk of enamel breakdown over 18 months of follow-up [20].

Also in this context, a 12-month clinical study evaluated the effectiveness of superficial infiltration with ICON® (DMG, Hamburg, Germany) in the attenuation of hypomineralized lesions of the crown of various etiologies. Seventeen patients with white enamel defects in the esthetic sector were selected. As a result, teeth affected by MIH showed partial attenuation in 8 cases, and in only one case the defect disappeared. Regarding the post-trauma cases, 6 were partially attenuated and 2 disappeared. Post-orthodontic defects disappeared in 6 cases and were attenuated in 5. All incipient caries defects were completely hidden. Four out of six cases of fluorosis have disappeared [21].

To elucidate these findings, a physicochemical characterization study evaluated the factors that influence the kinetics of resin infiltration of MIH lesions in permanent anterior teeth. Demarcated MIH lesions with the appearance of a homogeneous and heterogeneous lesion body, Types 1 ( $n = 14$ ) and 2 ( $n = 18$ ), respectively, were selected. After removing the surface layer of the lesion with a conical diamond bur, the lesions were conditioned and ethanol was applied to the lesions and it was determined whether the lesion was still visible or not. Type 1 lesions and positive

ethanol test had significantly lower mean Tmax (3.4 min) compared to type 2 lesions and negative ethanol test (9.9 min). A non-linear correlation ( $R^2 = 0.88$ ) was observed, indicating that the IPx was fast at the beginning of the resin application, decreasing over time. Therefore, compared to type 1 lesions and positive ethanol test, type 2 lesions and negative ethanol test require longer application time to infiltrate [22].

Besides, a 12-month study evaluated the aesthetic and functional efficacy of infiltrating resin (ICON®, DMG, Hamburg, Germany) in the treatment of Amelogenesis Imperfecta. Two adolescent patients, G.S. (13 years old) and C.M. (15 years old), affected by the type of hypomaturation of Amelogenesis Imperfecta, were treated with ICON® resin. Treated teeth present an excellent esthetic result immediately after application of the resin, an effect that lasts in the long term. Thus, resin infiltration proved to be a minimally invasive treatment for tooth discoloration, less aggressive than conventional procedures [23].

Also, a randomized controlled clinical trial comparatively analyzed the infiltration of ICON® resin and Clinpro™ XT varnish in the esthetic restoration of white spot lesions (WSLs) present after orthodontic treatment. Two hundred and forty WSLs were detected in 193 teeth of 12 patients. Participants were analyzed before the intervention (T0), immediately after the intervention (T1), 3 months later (T2) and 6 months later (T3), with a 1:1 allocation ratio for the application of ICON® resin infiltration. ® and Clinpro™ XT clearcoat. Immediately after the intervention, ICON® resin infiltration showed a statistically significant improvement better than Clinpro™ XT varnish in color restoration. However, at 3 and 6 months this was reversed. Therefore, Clinpro™ XT Varnish showed significantly better improvement than ICON® resin infiltration in restoring the color and luminosity of WSLs at 3 and 6 months. Fluorescence loss recovered significantly with both intervention methods between immediate application and at 6 months [24].

Finally, there is still no distinct understanding of the ultramorphology of enamel white spot lesions (WSLs). In this regard, one study characterized resin infiltration of WSLs using scanning electron microscopy. As a result, ICON® -Etch resulted in a series of funneled pits and holes in the WSL. Replicas of WSLs depicted shaggy resin tags from 0.5-6.0  $\mu\text{m}$  thick to a depth of 465  $\mu\text{m}$ . The resin infiltrant filled the spaces between the crystallites and resulted in a hybrid enamel layer. Thus, in addition to masking enamel WSLs, resin infiltration is able to involve residual enamel crystallites forming a hybrid enamel layer [25].

## Conclusion

Based on recent findings in the literature, the aesthetic results of ICON® infiltration proved to be effective, both in visual qualitative and quantitative spectrophotometric assessment. Furthermore, the infiltration of ICON® positively influenced the maintenance of the structural integrity of teeth affected by MIH, reducing the risk of enamel breakage. It also proved to be a minimally invasive treatment for tooth discoloration, less aggressive than conventional procedures. In addition to masking enamel white spot lesions, resin infiltration can involve residual enamel crystallites forming a hybrid enamel layer. Regarding the highest penetration and the highest percentages of penetration area, ICON® proved to be better than other resins such as Biscover LV (Bisco), Optiguard (Kerr Hawe), and Permaseal (Ultradent).

## Acknowledgement

Not applicable.

## Funding

Not applicable.

## Ethics approval

Not applicable.

## Informed consent

Not applicable.

## Data sharing statement

No additional data are available.

## Conflict of interest

The authors declare no conflict of interest.

## Similarity check

It was applied by Ithenticate@.

## About the License

© The authors (s) 2022. The text of this article is open access and licensed under a Creative Commons Attribution 4.0 International License.

## References

1. K.L. Weerheijm, B. Jalevik, S. Alaluusua, Molar-incisor hypomineralization, *Caries Res.* 35 (5) (2001) 390–391, <https://doi.org/10.1159/000047479>.
2. P.M. Schneider, M. Silva, Endemic molar incisor hypomineralization: A pandemic problem that requires monitoring by the entire health care community, *Curr. Osteoporos. Rep.* 16 (3) (2018) 283–288, <https://doi.org/10.1007/s11914-018-0444-x>.
3. B. Jalevik, GA Klingberg. Dental treatment, dental fear and behavior management problems in children with severe enamel hypomineralization of their permanent first molars, *Int. J. Paediatr. Dent.* 12 (1) (2002) 24–32, <https://doi.org/10.1046/j.0960-7439.2001.00318.x>.
4. K. Elhennawy, D.J. Manton, F. Crombie, P. Zaslansky, R.J. Radlanski, P.G. JostBrinkmann, F. Schwendicke, Structural, mechanical and chemical evaluation of molar-incisor hypomineralization-affected enamel: a systematic review, *Arch. Oral Biol.* 83 (2017) 272–281, <https://doi.org/10.1016/j.archoralbio.2017.08.008>.
5. C.M. Da Costa-Silva, G.M. Ambrosano, F. Jeremias, J.F. De Souza, F.L. Mialhe, Increase in severity of molar-incisor hypomineralization and its relationship with the colour of enamel opacity: a prospective cohort study, *Int. J. Paediatr. Dent.* 21 (5) (2011) 333–341, <https://doi.org/10.1111/j.1365-263x.2011.01128.x>.
6. G.C. Americano, P.E. Jacobsen, V.M. Soviero, D. Haubek, A systematic review on the association between molar incisor hypomineralization and dental caries, *Int. J. Paediatr. Dent.* 27 (1) (2017) 11–21, <https://doi.org/10.1111/ipd.12233>.
7. C.M. Bullio Fragelli, F. Jeremias, J. Feltrin de Souza, M.A. Paschoal, R. de C' assia Loiola Cordeiro, L. Santos-Pinto, Longitudinal evaluation of the structural integrity of teeth affected by molar incisor hypomineralisation, *Caries Res.* 49 (4) (2015) 378–383, <https://doi.org/10.1159/000380858>.
8. F.A. Crombie, D.J. Manton, J.E. Palamara, I. Zalizniak, N.J. Cochrane, E. C. Reynolds, Characterisation of developmentally hypomineralised human enamel, *J. Dent.* 41 (7) (2013) 611–618, <https://doi.org/10.1016/j.jdent.2013.05.002>.
9. P.L. Chay, D.J. Manton, J.E. Palamara, The effect of resin infiltration and oxidative pre-treatment on microshear bond strength of resin composite to hypomineralised enamel, *Int. J. Paediatr. Dent.* 24 (4) (2014) 252–267, <https://doi.org/10.1111/ipd.12069>.
10. A.K. Natarajan, S.J. Fraser, M.V. Swain, B.K. Drummond, K.C. Gordon, Raman spectroscopic characterisation of resin-infiltrated



- hypomineralised enamel, *Anal. Bioanal. Chem.* 407 (19) (2015) 5661–5671, <https://doi.org/10.1007/s00216-015-8742-y>.
11. F. Crombie, D. Manton, J. Palamara, E. Reynolds, Resin infiltration of developmentally hypomineralised enamel, *Int. J. Paediatr. Dent.* 24 (1) (2014) 51–55, <https://doi.org/10.1111/ipd.12025>.
  12. S. Paris, H. Meyer-Lueckel, Masking of labial enamel white spot lesions by resin infiltration—a clinical report, *Quintessence Int. (Berl)* 40 (9) (2009) 713–718.
  13. S. Kim, E.Y. Kim, T.S. Jeong, J.W. Kim, The evaluation of resin infiltration for masking labial enamel white spot lesions, *Int. J. Paediatr. Dent.* 21 (4) (2011) 241–248, <https://doi.org/10.1111/j.1365-263X.2011.01126.x>.
  14. S. Mastroberardino, G. Campus, L. Strohmer, A. Villa, M. Cagetti, An innovative approach to treat incisors hypomineralization (MIH): a combined use of casein phosphopeptide-amorphous calcium phosphate and hydrogen peroxide—a case report, *Case Rep. Dent.* 37959 (2012) 3, <http://dx.doi.org/10.1155/2012/379593>.
  15. Reynolds, Remineralization of enamel subsurface lesions by casein phosphopeptide-stabilized calcium phosphate solutions, *J. Dent. Res.* 76 (1997) 1587–1595.
  16. M. Sonesson, F. Bergstrand, S. Gizani, S. Twetman, Management of post-orthodontic white spot lesions: an updated systematic review, *Eur. J. Orthodontics* 39 (2) (2016) (cjw023).
  17. S. Paris, H. Meyer-Lueckel, Masking of labial enamel white spot lesions by resin infiltration—A clinical report, *Quintessence Int.* 40 (2009) 713–718.
  18. Theodory TG, Kolker JL, Vargas MA, Maia RR, Dawson DV. Masking and Penetration Ability of Various Sealants and ICON® in Artificial Initial Caries Lesions In Vitro. *J Adhes Dent.* 2019;21(3):265-272. doi: 10.3290/j.jad.a42520. PMID: 31093619.
  19. Mazur M, Westland S, Guerra F, Corridore D, Vichi M, Maruotti A, Nardi GM, Ottolenghi L. Objective and subjective aesthetic performance of ICON® treatment for enamel hypomineralization lesions in young adolescents: A retrospective single center study. *J Dent.* 2018 Jan;68:104-108. doi: 10.1016/j.jdent.2017.11.001. Epub 2017 Nov 28. PMID: 29104142.
  20. Nogueira VKC, Mendes Soares IP, Fragelli CMB, Boldieri T, Manton DJ, Bussanelli DG, Cordeiro RCL. Structural integrity of MIH-affected teeth after treatment with fluoride varnish or resin infiltration: An 18-Month randomized clinical trial. *J Dent.* 2021 Feb;105:103570. doi: 10.1016/j.jdent.2020.103570. Epub 2020 Dec 29. PMID: 33385533.
  21. Giannetti L, Murri Dello Diago A, Silingardi G, Spinass E. "Superficial infiltration to treat white hypomineralized defects of enamel: clinical trial with 12-month follow-up. *J Biol Regul Homeost Agents.* 2018 Sep-Oct;32(5):1335-1338. PMID: 30334435.
  22. Marouane O, Manton DJ. The influence of lesion characteristics on application time of an infiltrate applied to MIH lesions on anterior teeth: An exploratory in vivo pilot study. *J Dent.* 2021 Dec;115:103814. doi: 10.1016/j.jdent.2021.103814. Epub 2021 Sep 17. PMID: 34543698.
  23. Cagetti MG, Cattaneo S, Hu YQ, Campus G. Amelogenesis Imperfecta: A Non-Invasive Approach to Improve Esthetics in Young Patients. Report of Two Cases. *J Clin Pediatr Dent.* 2017;41(5):332-335. doi: 10.17796/1053-4628-41.5.332. PMID: 28872982.
  24. Kannan A, Padmanabhan S. Comparative evaluation of ICON® resin infiltration and Clinpro™ XT varnish on colour and fluorescence changes of white spot lesions: a randomized controlled trial. *Prog Orthod.* 2019 Jun 17;20(1):23. doi: 10.1186/s40510-019-0276-y. Erratum in: *Prog Orthod.* 2019 Jul 26;20(1):31. PMID: 31204437; PMCID: PMC6571438.
  25. Perdigão J. Resin infiltration of enamel white spot lesions: An ultramorphological analysis. *J Esthet Restor Dent.* 2020 Apr;32(3):317-324. doi: 10.1111/jerd.12550. Epub 2019 Nov 19. PMID: 31742888.

