



Preservation of the alveolar ridge in exodontia: a systematic review of the major aesthetic aspects

Karolyne Vicente Pereira^{1,2}, Gabriel Garcia Delgado^{1,2}, Carita Sebastiana Silva^{1,2},
Andreia Borges Scriboni^{1,2*}

¹ UNORTE - University Center of Northern São Paulo - Dentistry department, Sao Jose do Rio Preto, Sao Paulo, Brazil.

² UNIPOS - Post graduate and continuing education, Dentistry department, Sao Jose do Rio Preto, Sao Paulo, Brazil.

*Corresponding author: Dr. Andrea Borges Scriboni.

Unorp/Unipos – Graduate and Postgraduate and continuing education, Dentistry department, Sao Jose do Rio Preto, Sao Paulo, Brazil.

E-mail: abscriboni@hotmail.com

DOI: <https://doi.org/10.54448/mdnt22S313>

Received: 02-07-2022; Revised: 04-25-2022; Accepted: 04-27-2022; Published: 05-11-2022; MedNEXT-id: e22S313

Abstract

Introduction: In the work of implant placement in the post-extraction of single teeth, the esthetic zone has been a topic of great interest in the last 4 decades. Significant advances are being made in tissue biology knowledge in terms of post-extraction hard and soft tissue changes, helping to better understand the etiology of these esthetic complications. **Objective:** The present study carried out a concise systematic review of the tooth extraction process in light of minimally invasive extraction to preserve the esthetic area. **Methods:** The present study followed a concise systematic review model, following the rules of systematic review – PRISMA. The search strategy was carried out in the PubMed, Embase, Ovid, Cochrane Library, Web Of Science, and Scopus databases. The quality of the studies was based on the GRADE instrument, and the risk of bias was analyzed according to the Cochrane instrument. **Results and Conclusion:** A total of 104 studies were found and, after that, 36 studies of high to medium quality. As a result, it became evident that the extraction of a tooth initiates a series of reparative processes involving hard tissue (alveolar bone) and soft tissue (periodontal), gingiva). Alveolar bone changes after tooth extraction can compromise prosthetic rehabilitation. Alveolar ridge preservation has been proposed to limit these changes and improve prosthetic and esthetic results when implants are used. Alveolar ridge preservation techniques can minimize the overall changes in residual ridge height and width six months after extraction, but the evidence is very uncertain. There is no evidence of differences in the need for additional augmentation at the time of implant

placement, implant failure, esthetic outcomes, or any other clinical parameters due to a lack of long-term information or data.

Keywords: Exodontia. Dental extraction. Alveolar ridge. Dental implant. Minimally traumatic extraction. Aesthetic.

Introduction

In the work of implant placement in the post-extraction of single teeth, the esthetic zone has been a topic of great interest in the last 4 decades. Since the development of guided bone regeneration, the concept of immediate implant placement has advanced a lot, as several studies have indicated a significant risk for the development of mucosal recessions with immediate implants. Thus, significant advances are being made to the knowledge of tissue biology in terms of post-extraction hard and soft tissue changes, helping to better understand the etiology of these esthetic complications [1].

In this aspect, the esthetic results of implantology must be credible to those of conventional prostheses. The quantity and quality of hard and soft tissues play a key role in achieving the desired esthetics. Post-extraction implant dentistry is a treatment option for implant therapy after the extraction of a single tooth in the anterior mandible. Creating predictable peri-implant esthetics requires proper preservation of the bone and soft tissue around the teeth to be extracted and correct positioning of the 3D implant. Furthermore, esthetic success requires the creation of a correct transmucosal path during the provisional prosthetic phases, which must be replicated and maintained with the definitive

crowns [2].

Therefore, all extractions must be performed with precise indication, with defined prosthetic planning, thus avoiding imbalance in the patient's occlusion, swallowing, and aesthetics [3,4]. Thus, the professional must be able to offer the patient all rehabilitation options after extraction. It is necessary to preserve the alveolar bone at the implant site and adequate gingival contour (esthetic regions). For this, minimally traumatic extraction (MTE) techniques should be used [5], as the conventional extraction technique performed with levers and tweezers exerts horizontal movements and/or rotations on the tooth to be extracted, breaking the collagen fibers with bone expansion or buccal bone plate fracture [6]. Thus, MTE techniques aim to perform a vertical tooth extraction, preserving the alveolar bone [7]. In this sense, the principle of the new systems for extractions is that there is a minimum of bone expansion and trauma to the alveolus [7].

In this context, the new devices perform a traction force in the axial direction of the root of the tooth to be extracted and, if applied successfully, should minimize bone trauma, resulting in the rupture of periodontal fibers without bone expansion [8,9]. Still, some authors reported the immediate installation of implants in the socket of extracted teeth. The reason for this procedure is to reduce treatment time and cost, preserve height, alveolar bone thickness, and soft tissue dimension, promoting bone-implant contact [10-14].

Also, other steps and care must be taken to obtain the ideal position of the implant, such as the alignment of the implant in relation to the tooth to be restored and the position of the implant head must be located 3 mm apically to the apex of the cement-cement. The junction of the adjacent tooth allows uniformity of the cemental junction margin and accommodation of the abutment and prosthesis subgingivally [15,16]. It should also be considered that the buccal bone crest is vertically resorbed during the healing process [17]. This resorption process may be a consequence of the decrease in blood supply to the bone plate due to the folding of the mucoperiosteal flap [18]. Another factor to be evaluated after the installation of the immediate implant is the horizontal bone defect, also called the gap.

Therefore, based on these guidelines, the present study carried out a concise systematic review of the tooth extraction process in the light of minimally invasive extraction to preserve the esthetic area.

Methods

Study Design

The present study followed a concise systematic

review model, following the rules of systematic review - PRISMA (Transparent reporting of systematic reviews and meta-analysis-<http://www.prisma-statement.org/>).

Search Strategy and Sources

The search strategy was carried out in the PubMed, Embase, Ovid, Cochrane Library, Web Of Science, and Scopus databases, using descriptors: *Exodontia. Dental extraction. Alveolar ridge. Dental implant. Minimally traumatic extraction. Aesthetic*, and the use of Booleans "and" among descriptors and "or" among historical findings.

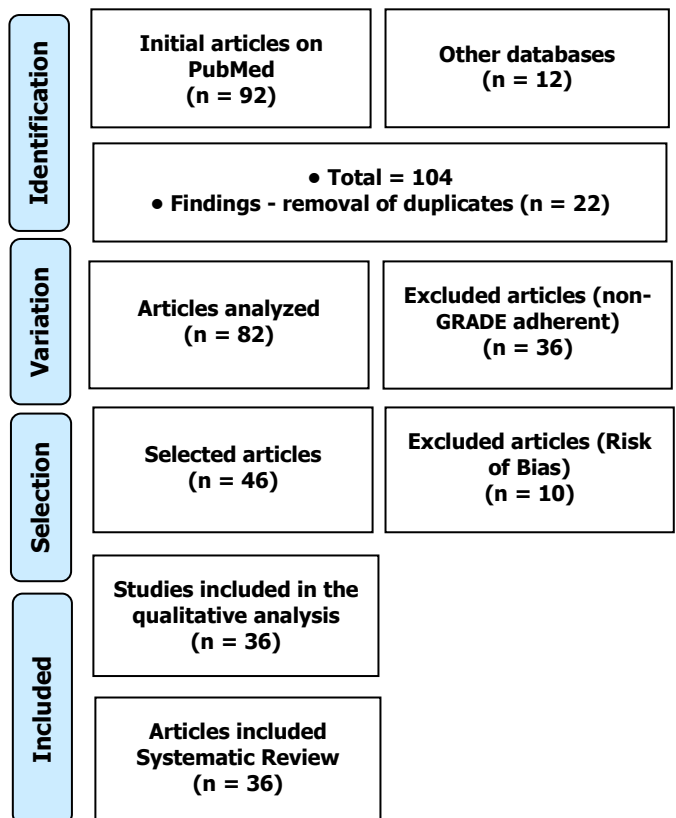
Study Quality and Bias Risk

The quality of the studies was based on the GRADE instrument, and the risk of bias was analyzed according to the Cochrane instrument.

Results and Discussion

A total of 104 studies were found and, after that, 36 studies of high to medium quality and with risks of bias were selected that do not compromise the scientific basis of the studies (Figure 1).

Figure 1. The selection process of scientific articles.



As a result, it became evident that the extraction of a tooth initiates a series of reparative processes involving hard tissues (alveolar bone) and soft tissues

(periodontal), gingiva) [19]. Thus, the bone healing process involves the inflammatory, reparative, and remodeling phases. The first phase is characterized by the formation of the clot, the second by the construction of the bone callus and the third is the remodeling and formation of new lamellar bone tissue.

In this regard, a review study analyzed the protocols for immediate, early, late, or later implant placement after tooth extraction. Results were at least 1 year after implant surgery. A total of 5,056 studies were found, of which 16 were included for qualitative analysis and 9 for quantitative analysis. The meta-analysis showed an increased risk of implant failure by 3% in the immediate implant protocol. The analysis showed no statistically significant difference between the early and late protocols. Subgroup analysis showed that the anterior region presented better results with immediate implants, while the molar region presented better results with delayed implants. Quantitative analysis showed no statistical difference in peri-implant bone resorption between immediate and delayed implant protocols [20].

In this context, alveolar bone changes after tooth extraction can compromise prosthetic rehabilitation. Alveolar ridge preservation has been proposed to limit these changes and improve prosthetic and esthetic results when implants are used. Thus, one study evaluated the clinical effects of various materials and techniques for alveolar ridge preservation after tooth extraction compared with extraction alone or other alveolar ridge preservation methods, or both, in patients requiring dental implant placement. After healing of extraction sockets. We included 16 RCTs performed worldwide involving a total of 524 extraction sites in 426 adult participants. Nine new trials were included in this update with six new trials in the category of comparing alveolar ridge preservation with isolated extraction and three new trials in the category of comparing different graft materials. As a result and conclusion, it was determined that alveolar ridge preservation techniques can minimize the overall changes in residual ridge height and width six months after extraction, but the evidence is very uncertain. There is no evidence of differences in the need for additional augmentation at the time of implant placement, implant failure, esthetic outcomes, or any other clinical parameters due to a lack of long-term information or data [21].

In this sense, studies show that after 6-8 weeks of healing, most of the granulation tissue is replaced by the temporary fibrous matrix and bone tissue, and the marginal part of the socket anchors islands of immature bone tissue [22-24]. Even at this stage, the provisional fibrous matrix and bone tissue occupy about 60% and 35% of the tissue [23]. These tissues are also

predominantly demonstrated at a later stage of healing (12-24 weeks), whereas lamellar and medullary bone is often less observed and represented. Thus, bone organization and architecture are generally incomplete within 24 weeks after tooth extraction [19].

Thus, all extractions must be performed with precise indication, due to the defined prosthetic planning. Also, they should be as painless, safe, and comfortable as possible. Thus, new management and extraction techniques have been tested and used [3-5]. In this sense, in dental implant therapy, the need to preserve as much alveolar bone as possible is of great importance. The placement of implants right after extraction has been much discussed in recent years, due to persistent clinical failures and also the buccal bone loss caused by the extraction itself [25,26].

Therefore, one of the alternatives to MTE is the use of membranes and grafts, used to preserve or recover bone volume after tooth extraction, either at the height or width of the alveolar crest, as well as to compensate for any type of bone loss due to tooth extraction. trauma [27]. However, these techniques have the disadvantage of increasing the cost, morbidity, and treatment time, in addition to making it impossible to place implants with immediate loading [28]. In addition, another method found in the literature that enters the context of minimal bone intervention is tooth exfoliation with orthodontic elastics. The method offers a gradual removal of the tooth and is more conservative than the dental extractor, however, as with grafting and membrane techniques, it has the disadvantage of requiring a longer treatment time, with an average extraction time of six weeks [28,29]. For patients using bisphosphonates for MTE, it seems to decrease the severity of postoperative complications, as bone loss is reduced with this technique [28,30].

Furthermore, the various MTE techniques have as their main objective the preservation of the buccal alveolar bone and the maintenance of the gingival contour after extraction. For example, we have the periotomes, bivers blade, and dental extractors [31-34]. The periotome is a surgical instrument that works by separating the periodontal ligament from the tooth. The instrument is placed in the groove between the periodontal ligament and the tooth, and the entire circumference of the tooth is contoured. The periotome most often reaches the fibers of the cervical and middle thirds. After separating the periodontal ligament and the tooth, extraction is performed with conventional instruments such as levers and forceps in an atraumatic way [31]. The bivers blade, as well as the periotome, aims to break the fibers of the periodontal ligament, facilitating the removal of the tooth with levers and/or forceps.

Besides, tooth extractors perform the extraction in the vertical direction, promoting an MTE [25,33,34]. In this sense, the main indications for dental extractors are when immediate implants will be performed, especially in esthetic areas and fractured teeth below the gingival margin, because with the use of the screw inserted in the residual root, flaps and osteotomies can be avoided. In addition, dental extractors can be used on any multirrooted or single-rooted tooth that is not in the context of contraindications, including fractured roots, non-retained tooth extractor screw, hypercementosis, root divergence in multirrooted teeth, and root lacerations [33].

In this sense, a study with 48 patients analyzed implants in sites with healed bone (control group) and sockets after tooth extraction (test group). In the test group, there was a gap less than or equal to 2 mm between the bone wall and the implant surface, while in the control group, the cortical bone was in direct contact with the implant. Membranes or filling materials were not used in the surgical sites, which, during healing, were covered by soft tissues. After 12 months of healing, histological analysis was performed and it was noted that the degree of bone in contact with the implant in all samples was high, between 62 and 71%, with no differences between the control group and the test group. The authors demonstrate that hard tissue can fill and occupy the marginal defects around the implant, at the extraction sites, during healing, and that the buccal and palatal portions of the bone crest after tooth removal suffer more loss of horizontal tissue and less vertical tissue loss [35].

Besides, one study analyzed the outcome of immediate post-extraction implants placed with and without bone graft in the maxillary premolar area for a 3-year follow-up after loading at an anesthetic level. After tooth extraction, 102 patients received 115 immediate dental implants. After 3 years, 1 implant failed in each group. Thirty-seven patients had inflammation and bleeding, 19 had mucositis and 2 had peri-implantitis. No statistically significant differences were found between the 2 groups. However, the Pink Esthetic Score and patient satisfaction were higher in group B than in group A. Therefore, the use of a bovine inorganic bone substitute with a resorbable collagen barrier in immediate post-extraction implants appears to improve esthetic results after 3 years of follow-up [36].

Conclusion

Alveolar ridge preservation techniques can minimize the overall changes in residual ridge height and width six months after extraction, but the evidence is very uncertain. There is no evidence of differences in

the need for additional augmentation at the time of implant placement, implant failure, esthetic outcomes, or any other clinical parameters due to a lack of long-term information or data. However, the use of an inorganic bovine bone substitute with a resorbable collagen barrier in immediate post-extraction implants appears to improve esthetic results after 3 years of follow-up.

Acknowledgement

Not applicable.

Funding

Not applicable.

Ethics approval

Not applicable.

Informed consent

Not applicable.

Data sharing statement

No additional data are available.

Conflict of interest

The authors declare no conflict of interest.

Similarity check

It was applied by Ithenticate@.

About the License

© The authors (s) 2022. The text of this article is open access and licensed under a Creative Commons Attribution 4.0 International License.

References

1. Buser D, Chappuis V, Belser UC, Chen S. Implant placement post extraction in esthetic single tooth sites: when immediate, when early, when late? *Periodontol* 2000. 2017 Feb;73(1):84-102. doi: 10.1111/prd.12170. PMID: 28000278.
2. Di Girolamo M, Cecchetti F, Volpe L, Baggi L, Mazza D, Turco M, Volpe S. Critical investigation of the pre-surgical anatomic factors that influence the aesthetic result in post-extractive implantology and immediate prosthetic. *J Biol Regul Homeost Agents*. 2021 May-Jun;35(3 Suppl. 1):127-137. doi: 10.23812/21-3suppl1-15. PMID: 34289672.
3. Suprakash B. et al. Knowledge and attitude of patients toward dental implants as an option for replacement of missing teeth. *J. Contemp. Dent*.

- Pract. Cincinnati, v. 14, no. 1, p.115-118,Jan./Feb. 2013.
4. Sardinha SCS. et al. Levantamento epidemiológico realizado na clínica de cirurgia bucal. Rev. Odonto Ciênc., Porto Alegre, v. 21, n. 53, p. 227-231, jul./set. 2006.
 5. Zafropoulos GG, Kasaj A, Hoffmann O. Immediate implant placement in fresh mandibular molar extraction socket: 8-year results. A case report. J Oral Implantol. 2010;36(2):145-51. doi: 10.1563/AAID-JOI-D-09-00030. PMID: 20426592.
 6. Saund D, Dietrich T. Minimally invasive tooth extraction doorknobs and strings revisited. Dental Update, Guildford, 2013, v. 40, no. 1, p. 325-330.
 7. Muska, E. et al. Atraumatic vertical tooth extraction: a proof of principle clinical study of a novel system. OralMaxillofac. Surg., Basel, 2013, v. 116, n. 5, p.303-310.
 8. Hornig, H. P.; Offermann, T. Implant preparation: atraumatic tooth extraction using easy X Trac system tooth extractor. Dent. Products Report, [S. l.], v. 7, no. 1, p. 68-69, 2005.
 9. Misch CE. Implantes dentários contemporâneos. Editora Santos: São Paulo; 2000.
 10. Denissen HW, Kalk W. Preventive implantations. Int Dent J 1991 Feb; 41(1):17-24.
 11. Gelb DA. Alteration of protocol to enhance esthetic and functional results of osseointegrated implants. Presented at the Annual Meeting of the American Academy of Periodontology. Oct 1991, Vancouver, British Columbia.
 12. Wheeler SL, Vogel RE, Casellini R. Tissue preservation and maintenance of optimum esthetics: a clinical report. Int J Oral Maxillofac Implants. 2000 Mar-Apr; 15(2):265-71.
 13. Schropp L, Kostopoulos L, Wenzel A. Bone healing following immediate versus delayed placement of titanium implants into extraction sockets: a prospective clinical study. Int J Oral Maxillofac Implants. 2003 Mar-Apr; 18(2):189-99.
 14. Lindhe J. Tratado de periodontia clínica e implantologia oral. Ed: Guanabara Koogan, 2005.
 15. Gelb DA. Immediate implant surgery: three-year retrospective evaluation of 50 consecutive cases. Int J Oral Maxillofac Implants. 1993; 8(4):388-99.
 16. Bianchini M. O Passo-a-Passo Cirúrgico na Implantodontia da Instalação à Prótese, Editora Livraria Santos: São Paulo, 2008, capítulo 11.
 17. Adell R, Lekholm U, Rockler B, Branemark PI. A 15-year study of osseointegrated implants in the treatment of the edentulous jaw. Int J Oral Surg. 1981 Dec; 10(6):387-416.
 18. Kois JC, Kan JY. Predictable peri-implant gingival aesthetics: surgical and prosthodontic rationales. Pract Proced Aesthet Dent.2001 Nov-Dec;13(9):691-8.
 19. Farina, R.; Trombelli, L. Wound healing of extraction sockets. Endod. Topics, Oxford, v. 25, no. 1, p. 16-43, 2011.
 20. Canellas JVDS, Medeiros PJD, Figueredo CMDS, Fischer RG, Ritto FG. Which is the best choice after tooth extraction, immediate implant placement or delayed placement with alveolar ridge preservation? A systematic review and meta-analysis. J Craniomaxillofac Surg. 2019 Nov;47(11):1793-1802. doi: 10.1016/j.jcms.2019.08.004. Epub 2019 Aug 27. PMID: 31522823.
 21. Atieh MA, Alsabeeha NH, Payne AG, Ali S, Faggion CMJ, Esposito M. Interventions for replacing missing teeth: alveolar ridge preservation techniques for dental implant site development. Cochrane Database Syst Rev. 2021 Apr 26;4(4):CD010176. doi: 10.1002/14651858.CD010176.pub3. PMID: 33899930; PMCID: PMC8092674.
 22. Amler, M. H.; Johnson, P.L.; Salman, I. Histological and histochemical investigation of human alveolar socket healing in undisturbed extraction wounds. J. Am. Dent. Assoc., Chicago, v. 61, p. 32-44, July 1960.
 23. Trombelli, L. et al. Modeling and remodeling of human extraction sockets. J. Clin. Periodontol, Copenhagen, v. 35, no. 7, p. 630-639, July 2008.
 24. Evian, C. I. et al. The osteogenic activity of bone removed from healing extraction sockets in humans. J. Periodontol., Chicago, v. 53, no. 2, p. 81-85, Feb. 1982.
 25. Thomé, G. et al. Indicações e limitações do uso do extrator dentário. J. ILAPEO, [S. l.], v. 6, n. 2, p. 85-88, abr./maio 2012.
 26. Nogueira, A.S. et al. Orientações pós-operatórias em cirurgia bucal. J. Bras. Clin. Odontol. Integr. [S. l.], p. 01-06, out. 2006. Edição especial.
 27. Salomão, M; Alvarez, F. K. Siqueira, J. T. T. Regeneração óssea guiada em defeitos extensos pós-exodontias utilizando membrana exposta ao meio bucal. ImplantNews, São Paulo, v. 7, n. 6, p. 753-759, nov./dez. 2010. 38
 28. Oghli, A. A.; Steveling, H. Ridge preservation following tooth extraction: a comparison

- between atraumatic extraction and socket seal surgery. *Quintessence Int.*, Berlin, v. 41, no.7, p. 605-609, July 2009.
- 29.** Regev, E.; Lustmann, J.; Nashef, R. Atraumatic teeth extraction in bisphosphonate-treated patients. *J. Oral Maxillofac.Surg.*, Philadelphia, v.66, no. 6, p. 1157-1161, May 2008.
- 30.** Schropp, L. et al. Bone healing and soft tissue contour changes following single-tooth extraction: a clinical and radiographic 12-month prospective study. *Int. J. Periodontics Restor.Dent.*, Chicago, v. 23, no. 1, p. 213-323, 2003.
- 31.** Dym, H.; Weiss, A. Exodontia: Tips and Techniques for Better Outcomes. *Dent.Clin. N. Am.*, New York, v. 56, no.1, p. 245-266, 2012.
- 32.** Oliveira, A. C. et al. Implante imediato unitário em função imediata – relato de caso. *RFO UPF, Passo Fundo*, v. 13, n. 1, p. 70-74, jan./abr. 2008.
- 33.** Babbush, C. A. A. New atraumatic system for tooth removal and immediate implant restoration. *Implant Dent.*, Baltimore, v. 6, no.2, p. 139-145, June 2007.
- 34.** Meneses, D. R. Exodontia traumática e previsibilidade em reabilitação oral com implantes osseointegráveis: relato de casos clínicos aplicando o Sistema Brasileiro de Exodontia Atraumática Xt Lifting®. *Rev. Port. Estomatol. Cir. Maxilofac.*, Lisboa, v. 50, n. 1, p. 11-17, 2009.
- 35.** Paolantonio M, Dolci M, Scarano A, d'Archivio D, di Placido G, Tumini V. Immediate implantation in fresh extraction sockets. A controlled clinical and histological study in man. *J Periodontol.* 2001 Nov; 72(11):1560-71.
- 36.** Mastrangelo F, Gastaldi G, Vinci R, Troiano G, Tettamanti L, Gherlone E, Lo Muzio L. Immediate Postextractive Implants With and Without Bone Graft: 3-year Follow-up Results From a Multicenter Controlled Randomized Trial. *Implant Dent.* 2018 Dec; 27(6):638-645. doi: 10.1097/ID.0000000000000816. PMID: 30260821.