



Main approaches of three-dimensional (3D) imaging examinations in the assessment, treatment, and follow-up of patients with skeletal Class III: a concise systematic review

Isabel Guadalupe Solano Burbano^{1,2,3*}, Sandra Dioni Lara Guzman^{1,2,3}, Eduardo Sant'ana^{2,3}, Gastão Moura Neto^{2,3}, Renata Furquim Moura^{2,3}

¹ Dentistry Department, Quito, Ecuador.

² UNORP - University Center North Paulista - Sao Jose do Rio Preto, Sao Paulo, Brazil.

³ UNIPOS - Post graduate and continuing education, Sao Jose do Rio Preto, Sao Paulo, Brazil.

*Corresponding author: Isabel Guadalupe Solano Burbano. Quito, Ecuador.

E-mail: isabelsb_2007@hotmail.com

DOI: <https://doi.org/10.54448/mdnt22S205>

Received: 10-11-2021; Revised: 12-15-2021; Accepted: 12-18-2021; Published: 03-29-2022; MedNEXT-id: e22S205

Abstract

Introduction: Class III malocclusion presents with several skeletal and dental factors, highlighting the large or protruding jaw, retrusive maxilla, protrusive mandibular dentition, retrusive maxillary dentition, or combinations. The importance of evaluating class III malocclusions, as well as their treatments, through three-dimensional (3D) images are highlighted.

Objective: To present a concise systematic review of the approach of 3D imaging exams to conduct class III malocclusion treatments, as well as to follow up after orthognathic surgery. **Methods:** Clinical studies with qualitative and/or quantitative analysis were included, following the rules of the systematic review-PRISMA.

Results and Conclusion: A total of 105 articles was found involving class III malocclusion and ortho-surgical treatments guided by three-dimensional (3D) images. A total of 44 articles were fully evaluated and 16 were included and discussed in this study. Positional, structural, and volumetric condylar changes after orthognathic surgery in skeletal Class III patients have been well elucidated using cone-beam computed tomography. In addition, the virtual surgical planning and the surgical splint manufactured in CAD/CAM facilitate treatment planning and offer an accurate surgical result in orthognathic surgery. The application of pre-engineered bone guidance splints allows the treatment of craniofacial deformities with precision. Therefore, the three-dimensional (3D) tool allows for the accuracy of treatments and planning of orthognathic surgery, as well as the best postoperative follow-up.

Keywords: Class III malocclusion. Assessments. Treatments. Three-dimensional images (3D).

Introduction

In the context of orthodontics and skeletal classifications of the mandible and maxilla, Class III malocclusion presents with various skeletal and dental factors, highlighting the large or protruding mandible, retrusive maxilla, protrusive mandibular dentition, maxillary retrusive dentition, or combinations [1,2]. In this scenario, it is very difficult to make the diagnosis and prognosis, making treatment a challenge [3].

Furthermore, the improvement of class III skeletal malocclusion can be achieved by growth modification [4], orthodontic camouflage, or orthognathic surgery [5]. In this regard, factors such as the patient's age, the severity of the malocclusion, the patient's main complaint, clinical examinations, and cephalometric analysis will outline the best treatment [6].

In this sense, the severity of class III malocclusion in adults would define adherence for surgery or orthodontic treatment [7]. Therefore, authors have suggested that surgery should be performed in patients with ANB and mandibular incisor plane angles lower than -4° and 83° , respectively [8]. Still, other authors also performed a study to differentiate class III patients with only orthodontic or surgical treatment [9]. Furthermore, authors have suggested that the Holdaway angle can be a reliable guide to determine the modality of treatment for these patients. They further suggested that patients with a Holdaway angle greater than 12° can be successfully treated only by orthodontics, whereas patients with a Holdaway angle less than 12° require surgical treatment [10]. Added to this, another study showed that patients with a borderline angular value above 7.2° can be successfully

treated only by orthodontics.

In this context, the importance of assessments of class III malocclusions is highlighted, as well as their treatments, through three-dimensional (3D) images [11]. For this, it is necessary to discuss the advantages, disadvantages, and pitfalls of virtual three-dimensional surgical planning compared to traditional two-dimensional (2D) planning methods in orthognathic surgery [12].

Therefore, this study aimed to present a concise systematic review of the approach of 3D imaging exams to conduct class III malocclusion treatments, as well as to follow up after orthognathic surgery.

Methods

Study Design

The present study was followed by a systematic literature review model, according to the PRISMA rules. Access available at: <http://www.prisma-statement.org/>

Data sources and research strategy

The search strategies for this review were based on the descriptors: “Class III malocclusion. Assessments. Treatments. Three-dimensional images (3D)”. The research was carried out from August 2021 to September 2021 and developed based on Google Scholar, Scopus, PubMed, Scielo, and Cochrane Library.

Study quality and risk of bias

The quality of the studies was based on the GRADE instrument, with randomized controlled clinical studies, prospective controlled clinical studies, and studies of systematic review and meta-analysis listed as the studies with the greatest scientific evidence. The risk of bias was analyzed according to the Cochrane instrument.

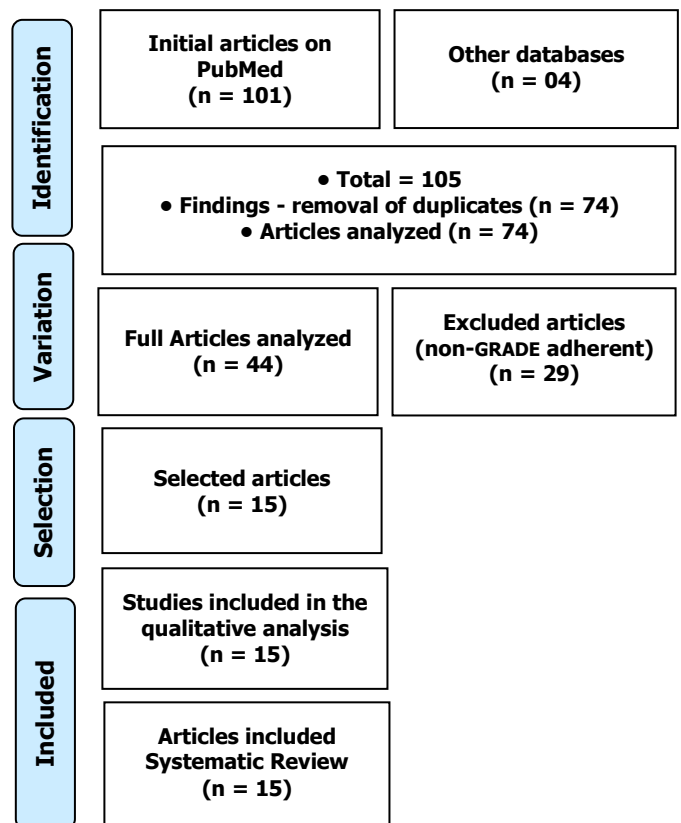
Results

A total of 105 articles was found involving class III malocclusion and ortho-surgical treatments guiados por imagens tridimensionais (3D). Initially, the existing title and duplications were excluded according to the interest described in this work. After this process, the abstracts were evaluated and a new exclusion was performed. A total of 44 articles were fully evaluated and 15 were included and discussed in this study (Figure 1).

After analyzing the studies found, a study outlined diagnostic measures in borderline cases of class III to choose the appropriate treatment. Pretreatment lateral cephalograms of 65 patients with moderate skeletal class III were analyzed. The camouflage group

consisted of 36 patients with a mean age of 23.5 years, and the surgery group consisted of 29 patients with a mean age of 24.8 years. Holdaway's H angle and Wits' assessment were able to differentiate patients suitable for orthodontic camouflage or surgical treatment. Cases with a retention angle greater than 10.3° and reasoning assessment greater than -5.8 mm would be successfully treated by camouflage, while those with a retention angle of less than 10.3° and reasoning assessment less than -5.8 mm can be treated surgically. Thus, there was an 81.5% success in classifying patients [1].

Figure 1. The selection process of scientific articles.



In this context, one study examined the positional, structural, and volumetric condylar changes after orthognathic surgery in skeletal Class III patients using cone-beam computed tomography. The condyle position was found changed immediately after surgery in the maxillary single mandible surgery group, but at one year follow-up, the condyles returned to their presurgical position. There was no significant difference in condylar position when comparing pre-surgery and one-year follow-up in any of the study groups. Condylar rotations in the axial and coronal planes were significant in the bimaxillary surgery group. No radiological signs of condylar bone degeneration were detected one year after surgery. Therefore, there were no significant changes in the positional, structural, or volumetric states of the condyles after one year [11].

In this sense, the advantage of computer-aided

planning in orthognathic surgery is highlighted. A study with 10 patients evaluated the accuracy of a virtual orthognathic surgical plan using three-dimensional (3D) analysis. A virtual surgical plan was performed by combining a 3D skull model acquired by computed tomography (CT) and surface scanning of the upper and lower dental arch, respectively, and final occlusal position. The parameters showed that the virtual surgical plans were successfully transferred with the aid of a surgical splint manufactured in CAD/CAM. Still, no statistically significant deviation between the surgical plan and the postoperative result could be detected. Thus, virtual surgical planning and the surgical splint manufactured in CAD / CAM facilitate treatment planning and offer an accurate surgical result in orthognathic surgery [13].

Also, a study with 30 adult patients with a mean age of 20.6 ± 1.5 years (female/male = 18/12) and with skeletal Class III malocclusion requiring 2-mandible orthognathic surgery was included in the study. Three-dimensional imaging data from 1-month preoperative CT (T1) and 6-month postoperative CT (T2) were compared to assess planning accuracy. The geographic changes of the overall overlap between the planned and postsurgical images were 0.60 ± 0.19 mm (range: 0.42-1.08 mm). The discrepancies between ANB, A-Nv, simulated and post-surgical Pog-Nv were $1.16 \pm 0.36^\circ$, 1.25 ± 0.33 mm, 1.19 ± 0.35 mm, respectively. Deviations between the simulated and post-surgical positions of Point A and Point B were within 1 mm in the horizontal and vertical directions. The application of pre-engineered bone guidance splints allows the treatment of craniofacial deformities with precision [14].

Finally, a study validated a three-dimensional (3D) tool to assess the accuracy of orthognathic surgery planning and postoperative follow-up. Fifteen patients (four men, 11 women; mean age 29.6 years) with skeletal classes II and III who underwent bimaxillary surgery were recruited for the study. All patients had preoperative computed tomography (CT) and cone-beam computed tomography (CBCT) 1 to 6 weeks and 6 months postoperatively. Inter- and intra-observer reliability was considered high (ICC range: 0.94-0.98) with mean variability of less than 0.4 mm and 0.7° for translational and rotational movements for precision planning and follow-up protocols. The study provided a reliable, quantitative, and rapid method to assess the accuracy of virtual surgical planning and postoperative follow-up [15].

Conclusion

Positional, structural, and volumetric condylar changes after orthognathic surgery in skeletal Class III

patients have been well elucidated using cone-beam computed tomography. In addition, the virtual surgical planning and the surgical splint manufactured in CAD/CAM facilitate treatment planning and offer an accurate surgical result in orthognathic surgery. The application of pre-engineered bone guidance splints allows the treatment of craniofacial deformities with precision. Therefore, the three-dimensional (3D) tool allows for the accuracy of treatments and planning of orthognathic surgery, as well as the best postoperative follow-up.

Acknowledgement

Not applicable.

Funding

Not applicable.

Data sharing statement

No additional data are available.

Conflict of interest

The authors declare no conflict of interest.

Similarity check

It was applied by Ithenticate@.

About the License

© The authors (s) 2022. The text of this article is open access and licensed under a Creative Commons Attribution 4.0 International License.

References

1. Eslami S, Faber J, Fateh A, Sheikholammeh F, Grassia V, Jamilian A. Treatment decision in adult patients with class III malocclusion: surgery versus orthodontics. *Prog Orthod*. 2018 Aug 2;19(1):28. doi: 10.1186/s40510-018-0218-0. PMID: 30069814; PMCID: PMC6070451.
2. Perillo L, Vitale M, Masucci C, D'Apuzzo F, Cozza P, Franchi L. Comparisons of two protocols for the early treatment of class III dentoskeletal disharmony. *Eur J Orthod*. 2016;38(1):51-6.
3. Jamilian A, Cannavale R, Piancino MG, Eslami S, Perillo L. Methodological quality and outcome of systematic reviews reporting on orthopaedic treatment for class III malocclusion: overview of systematic reviews. *J Orthod*. 2016;43:102-20.
4. Showkatbakhsh R, Jamilian A, Ghassemi M, Ghassemi A, Taban T, Imani Z. The effects of facemask and reverse chin cup on maxillary deficient patients. *J Orthod*. 2012;39:95-101.

5. Ngan P, Wilmes B, Drescher D, Martin C, Weaver B, Gunel E. Comparison of two maxillary protraction protocols: tooth-borne versus bone-anchored protraction facemask treatment. *Prog Orthod.* 2015;16:26.
6. Perillo L, Femminella B, Farronato D, Baccetti T, Contardo L, Perinetti G. Do malocclusion and Helkimo Index ≥ 5 correlate with body posture? *J Oral Rehabil.* 2011;38:242–52.
7. Perillo L, Monsurro A, Bonci E, Torella A, Mutarelli M, Nigro V. Genetic association of ARHGAP21 gene variant with mandibular prognathism. *J Dent Res.* 2015;94:569–76.
8. Kerr WJ, Miller S, Dawber JE. Class III malocclusion: surgery or orthodontics? *Br J Orthod.* 1992;19:21–4.
9. Stellzig-Eisenhauer A, Lux CJ, Schuster G. Treatment decision in adult patients with class III malocclusion: orthodontic therapy or orthognathic surgery? *Am J Orthod Dentofac Orthop.* 2002;122:27–37. discussion – 8
10. Rabie AB, Wong RW, Min GU. Treatment in borderline class III malocclusion: orthodontic camouflage (extraction) versus orthognathic surgery. *Open Dent J.* 2008;2:38–48.
11. Podčernina J, Urtāne I, Pirttiniemi P, Šalms G, Radziņš O, Aleksejūnienė J. Evaluation of Condylar Positional, Structural, and Volumetric Status in Class III Orthognathic Surgery Patients. *Medicina (Kaunas).* 2020 Dec 6;56(12):672. doi: 10.3390/medicina56120672. PMID: 33291272; PMCID: PMC7762172.
12. Donaldson CD, Manisali M, Naini FB. Three-dimensional virtual surgical planning (3D-VSP) in orthognathic surgery: Advantages, disadvantages and pitfalls. *J Orthod.* 2021 Mar;48(1):52-63. doi: 10.1177/1465312520954871. Epub 2020 Sep 28. PMID: 32988276.
13. Chin SJ, Wilde F, Neuhaus M, Schramm A, Gellrich NC, Rana M. Accuracy of virtual surgical planning of orthognathic surgery with aid of CAD/CAM fabricated surgical splint-A novel 3D analyzing algorithm. *J Craniomaxillofac Surg.* 2017 Dec;45(12):1962-1970. doi: 10.1016/j.jcms.2017.07.016. Epub 2017 Jul 29. PMID: 29066041.
14. Chang YJ, Lai JP, Tsai CY, Wu TJ, Lin SS. Accuracy assessment of computer-aided three-dimensional simulation and navigation in orthognathic surgery (CASNOS). *J Formos Med Assoc.* 2020 Mar;119(3):701-711. doi: 10.1016/j.jfma.2019.09.017. Epub 2019 Oct 22. PMID: 31653575.
15. Shaheen E, Shujaat S, Saeed T, Jacobs R, Politis C. Three-dimensional planning accuracy and follow-up protocol in orthognathic surgery: a validation study. *Int J Oral Maxillofac Surg.* 2019 Jan;48(1):71-76. doi: 10.1016/j.ijom.2018.07.011. Epub 2018 Aug 3. PMID: 30082193.

